

# EASL Clinical Practice Guidelines: Vascular diseases of the liver<sup>☆</sup>

European Association for the Study of the Liver<sup>\*</sup>

## Introduction

Vascular disorders of the liver, although affecting less than 5/10,000 patients, collectively account for a number of rare conditions that represent an important health problem worldwide in the field of liver diseases. A common characteristic of most of these disorders is that they can cause non-cirrhotic portal hypertension with an ensuing high morbidity and mortality. In addition, special relevance addresses the fact that patients are usually young with an otherwise normal life expectancy that may be markedly shortened if they are not adequately managed.

Advances in the knowledge of vascular liver disorders are hampered by the small number of cases and a limited number of studies assessing natural history, pathophysiology or therapy. However, in recent years, interest for these disorders has increased as reflected in the rise in the number of publications on this topic. In addition, EASL has encouraged this increased interest by sponsoring a monothematic conference in June 2012 in Tallinn on vascular disorders of the liver, and by proposing an EASL clinical practice guidelines on the issue. These guidelines will not cover all possible vascular disorders of the liver but are mainly based on the subjects discussed during the monothematic conference; Budd-Chiari syndrome, non-cirrhotic portal vein thrombosis, idiopathic portal hypertension, sinusoidal obstruction syndrome, hepatic vascular malformations in hereditary haemorrhagic telangiectasia and portal vein thrombosis in cirrhosis.

Guidelines have been written according to published studies retrieved from Pubmed. The evidence and recommendations have been graded according to the Grading of Recommendations Assessment Development and Evaluation (GRADE) system. The strength of evidence has been classified into three levels: high (A), moderate (B) or low quality (C), while the grade of recommendation in two levels: strong (1) or weak (2) (Table 1). The higher the quality of the evidence, the more likely a strong recommendation is warranted. Where no clear evidence existed, recommendations were based on agreed opinions of the writing committee members.

Received 20 July 2015; accepted 20 July 2015

Contributors: Chairman: Juan Carlos García-Pagán; Panel members: Elisabetta Buscarini, Harry L.A. Janssen, Frank W.G. Leebeek, Aurelie Plessier, Laura Rubbia-Brandt; Marco Senzolo, Jeffrey N.L. Schouten, Armando Tripodi. EASL governing board member: Dominique C. Valla.

\* Correspondence: EASL Office, 7 Rue Daubin, CH 1203 Geneva, Switzerland.

E-mail address: [easloffice@easloffice.eu](mailto:easloffice@easloffice.eu).



ELSEVIER

## Aetiological factors in splanchnic vein thrombosis in patients without underlying liver disease

In the last decades several aetiological factors for splanchnic vein thrombosis (SVT), including Budd-Chiari syndrome (BCS) and portal vein thrombosis (PVT), have been identified. These can be divided into local and systemic factors. Local risk factors for the development of BCS include solid malignancies or cysts that compress the venous tract [1]. PVT is most often seen as a complication of liver cirrhosis or hepatobiliary malignancies. Other local risk factors are intra-abdominal surgery and infections or inflammation in the abdomen. Systemic risk factors can be identified in most patients with SVT. In a large multicentre European En-Vie study on patients with BCS (n = 163) and PVT (n = 105), prothrombotic factors were present in up to 84% and 42%, respectively [2,3] (Table 2). These data are consistent with earlier retrospective studies using similar diagnostic tools [4,5]. In other parts of the world, especially in Asia other aetiological factors are observed, including Behçet disease, webs (also known as membranous obstruction) of the inferior vena cava (IVC) and hydatid cysts [6,7]. Most studies have been performed in adults with SVT. In children with SVT prothrombotic factors seem to play an important aetiological role, however SVT may also be caused by age-specific factors, such as neonatal sepsis and umbilical catheterisation [8]. The aetiology of BCS and PVT is often multifactorial. In the En-Vie study a combination of two or more genetic or acquired prothrombotic factors occurred in 46% of BCS and 10% of PVT patients [2,3]. In PVT a prothrombotic factor was found in 36% of patients with a local risk factor [3]. In BCS patients, 18% of the patients even had three risk factors. In over 60% of SVT patients diagnosed with inherited thrombophilia an additional risk factor was found.

### Inherited and acquired thrombophilia

The term “thrombophilia” defines both inherited and acquired conditions that are associated with an increased risk of venous thrombosis, and is characterized by a hypercoagulable state [9]. Both inherited deficiencies of natural inhibitors of the coagulation system, increased levels of coagulation factors and genetic mutations of coagulant factors are associated with an increased risk of SVT. The prevalence of inherited deficiencies of antithrombin, protein C and protein S are difficult to assess in SVT patients, a result of decreased liver synthesis which is often encountered in these patients. Also treatment with vitamin K antagonists (VKA) hampers the diagnosis of protein C and protein S deficiency. The prevalence of antithrombin deficiency ranges between 0–5% in both BCS and PVT, of protein C deficiency between

# Clinical Practice Guidelines

**Table 1. Evidence and recommendation grading (adapted from the GRADE system).**

Grading of evidence	Notes	Symbol
High quality	Further research is very unlikely to change our confidence in the estimate of effect	A
Moderate quality	Further research is likely to have an important impact on our confidence in the estimate of effect and may change the estimate	B
Low or very low	Further research is very likely to have an important impact on our confidence in the estimate of effect and is likely to change the estimate. Any estimate of effect is uncertain	C
Grading recommendation	Notes	Symbol
Strong recommendation warranted	Factors influencing the strength of the recommendation included the quality of evidence, presumed patient-important outcomes, and cost	1
Weaker recommendation	Variability in preferences and values, or more uncertainty: more likely a weak recommendation is warranted Recommendation is made with less certainty: higher cost or resource consumption	2

**Table 2. Aetiological factors in Budd-Chiari syndrome and portal vein thrombosis [48,52,73].**

Risk factor	BCS	PVT
	Frequency (%)	Frequency (%)
Thrombophilia		
Inherited	21	35
Acquired	44	19
Myeloproliferative neoplasm	49	21
JAK2 pos	29	16
Hormonal factors	38	44
Oral contraceptives	33	44
Pregnancy	6	0
PNH	19	0
Other systemic factors	23	n.d.
Local factors	0	21

BCS, Budd-Chiari syndrome; PVT, portal vein thrombosis; PNH, paroxysmal nocturnal haemoglobinuria; n.d, no date.

4–20% in BCS and 0–7% in PVT, and of protein S deficiency between 0–7% in BCS and 0–30% in PVT [2–4,10–12]. Because this is strikingly higher than in the general population, deficiencies of these coagulation inhibitors are considered an aetiological factor in the pathogenesis of BCS and PVT, and should be included in the diagnostic work-up.

In BCS patients the prevalence of Factor V Leiden mutation (FVL) ranges between 7% and 32%. Most of these BCS patients are heterozygous carriers, although homozygous patients have been described occasionally [13]. It is well known that homozygote carriers have a significantly higher risk of deep vein thrombosis compared to heterozygotes, however this has not been demonstrated for SVT. The prevalence of the FVL mutation in patients with PVT is lower, ranging between 3% and 9% [14]. FVL carriers have a 4- to 11-fold increased risk of BCS, and a 2-fold risk of PVT [15]. Prothrombin *G20210A* gene variant is more common in PVT than in BCS [14]. A meta-analysis reported a 4- to 5-fold increase in the risk of PVT in carriers of the prothrombin *G20210A* gene variant [15], whereas the risk of BCS is approximately 2-fold increased [10]. The mechanism for the difference

in prevalence of FVL and the prothrombin *G20210A* gene variant in BCS and PVT remains unresolved. The prevalence of antiphospholipid antibodies (APA) in BCS and PVT has been estimated to be around 5–15% [2–4]. However, in most studies only one measurement of APA was carried out, whereas according to the current guidelines this measurement should be repeated after 12 weeks in order to confirm presence of APA [16].

In addition to the above mentioned risk factors for SVT, more recent studies have investigated whether increased levels of pro-coagulant factors or disorders of fibrinolysis are associated with an increased risk of SVT. Elevated factor VIII levels are found in patients with PVT [17,18]. A significant increase of endogenous thrombin irrespective of the underlying prothrombotic or thrombophilic disorder was also observed in PVT [18]. Hypofibrinolysis, defined by an increase of clot lysis time, was also associated with an increased risk of BCS. This was mainly determined by increased plasminogen activator inhibitor-1 levels. So far the importance of these findings for prognosis and treatment of SVT has not been studied [19].

### Myeloproliferative neoplasms

Myeloproliferative neoplasms (MPNs) are a common underlying cause of abdominal vein thrombosis. MPNs are chronic clonal haematopoietic stem cell disorders characterized by an overproduction of mature and functional granulocytes, red blood cells and/or platelets. One of the main complications of MPNs is the development of arterial and venous thrombotic complications caused by increased platelet aggregation and thrombin generation [19,20]. It has previously been estimated that MPNs are observed in 30–40% of patients with BCS or PVT, whereas this is the cause in only a minority of other types of venous thromboembolism [2,3,11,21,22]. MPN is diagnosed based on several criteria including the characteristic peripheral blood cell changes (increased haemoglobin levels and thrombocytosis) and bone marrow findings. In SVT patients however the relevance of these commonly used criteria for the diagnosis of MPN is debated. Due to portal hypertension leading to hypersplenism and haemodilution the characteristic thrombocytosis and erythrocytosis may be masked [23]. Previously, diagnosis of MPNs in these patients relied on bone marrow (BM) biopsy findings and growth of erythroid colonies in the absence of exogenous erythropoietin,

referred to as spontaneous endogenous erythroid colonies or EEC. This could also be used to identify patients at risk of aggravation of MPN [23]. Nowadays the *JAK2V617F* mutation, a common gain-of-function mutation leading to the development of MPN, is of major importance in the diagnostic strategy of MPN. This mutation is present in nearly all patients with polycythemia vera and in about 50% of patients with essential thrombocythemia and primary myelofibrosis. The *JAK2V617F* mutation has been detected in a large number of unselected BCS and PVT patients. In a recent meta-analysis the prevalence of MPNs and their subtypes as well as *JAK2V617F* and its diagnostic role in these uncommon disorders was reported [24]. In BCS, mean prevalence of MPNs and *JAK2V617F* was 40.9% and 41.1%, respectively. In PVT, mean prevalence of MPNs and *JAK2V617F* was 31.5% and 27.7%, respectively. MPN and *JAK2V617F* were more frequent in BCS compared to PVT. Polycythemia vera was more prevalent in BCS than in PVT. *JAK2V617F* screening in SVT patients without typical haematological MPN features identified MPN in 17.1% and 15.4% of screened BCS and PVT patients, respectively [24]. It can be concluded that in all patients with SVT BM histology and screening for *JAK2V617F* should be performed as part of the standard diagnostic work-up [25]. In some cases, MPN is difficult to diagnose and additional tests, such as peripheral blood smear, erythropoietin levels or endogenous erythroid colony formation *in vitro* may be added to the diagnostic algorithm, as suggested by the WHO [26]. Recently two research groups simultaneously reported the presence of somatic mutations in the gene encoding calreticulin (CALR), a protein present in the endoplasmic reticulum and involved in the regulation of STAT-signalling pathway [27,28]. These mutations were detected using whole exome sequencing in the majority of patients with MPN with non-mutated JAK2. CALR mutations were absent in polycythemia vera patients, and occurred in up to 80% of patients with JAK2 negative essential thrombocythemia and primary myelofibrosis. In two recent studies [29,30], CALR mutations were evaluated in patients with SVT being positive in 0.7 and 1.9% of patients respectively. The rate increased when only patients with MPN were considered (2.3 and 5.4% respectively). Indeed, CALR was found positive in respectively 9.1% (1 out of 11 patients) and 30% (4 out of 13 patients) of JAK2 negative MPN.

The exact pathogenetic mechanism of SVT in MPNs still remains to be resolved, but besides characteristic erythrocytosis and thrombocytosis, platelet and leukocyte functional abnormalities seem to have a pathogenetic role [31].

#### Other aetiological factors

Paroxysmal nocturnal haemoglobinuria (PNH) is a rare acquired haematological disorder of haematopoietic stem cells and is most strongly associated with BCS [32]. PNH has been reported in 9–19% of tested BCS patients [11,33], whereas a prevalence of 0–2% has been reported in PVT [3]. The exact mechanism for the development of SVT is yet unknown [33]. Patients with a PNH cell population above 60% of the granulocytes appear to be at a greater risk for thrombosis [34]. Testing for PNH should routinely be performed in all BCS and considered in PVT patients [35]. Autoimmune-mediated diseases, inflammatory bowel

disease, vasculitis, sarcoidosis and connective tissue disease may also be associated with SVT, although these disorders were hardly observed in the En-Vie study, Behçet's disease is especially observed in the Mediterranean area [36]. Other rare causes of SVT include cytomegalo-virus infections and celiac disease [37,38].

Hormonal factors, including oral contraceptive use and pregnancy are considered risk factors for SVT. Oral contraceptives have been shown to be associated with at least a 2-fold risk for BCS [10,39]. For PVT the risk may be slightly increased, but this has not yet been well-established [10]. It should be noted that in many patients other concomitant aetiological factors were identified.

#### Aetiological factors and their importance for treatment

Diagnosing the underlying aetiological factor for developing SVT is important, since it may have therapeutic or prognostic implications. For instance, the presence of a prothrombotic disorder may influence the duration of anticoagulant treatment in PVT patients. For patients with BCS, lifelong anticoagulant treatment is warranted considering the severity of the disorder. In individuals with acute PVT, anticoagulant therapy is given for 6 months. However, long-term treatment is sometimes given, depending upon the underlying disorder. In general, the duration of anticoagulant therapy is strongly dependent upon the risk of recurrent thrombosis. Although only a few retrospective studies have focused on the risk of recurrence in PVT, these studies revealed that an underlying prothrombotic state was an independent predictor of recurrent thrombosis [40–42]. On the other hand, the risk of bleeding in these patients, who frequently present with variceal bleeding, should be taken into account. Therefore recent guidelines have suggested long-term anticoagulant therapy only to those individuals with major underlying thrombophilic risk factors, such as homozygous FVL mutation and prothrombin gene variant [43]. However, other guidelines state that thrombophilic defects has an uncertain predictive value for recurrence and decisions regarding duration of anticoagulant treatment if the result of testing is not evidence-based [44]. Follow-up studies are needed to establish the duration of anticoagulant treatment especially those with no or mild thrombophilic disorders. Current guidelines do not support the testing of other family members in case a thrombophilia defect is identified [45].

In case of an underlying MPN, anticoagulant treatment with VKA should be given indefinitely for SVT. Nearly all MPN patients nowadays are treated with aspirin. However it is yet unknown whether aspirin should be added to the treatment of SVT patients with MPN using VKA. Although a potential benefit of aspirin in patients with PVT and MPN was observed in a retrospective study, this should be confirmed in prospective studies [44,46]. MPN patients should be treated with anti-proliferative therapy, such as alpha interferon or hydroxyurea, in order to normalise peripheral blood cell counts. In patients with polycythemia vera a haematocrit <45% should be aimed for [47]. The diagnosis of underlying PNH in patients with SVT may have important implications for treatment. Long-term treatment with eculizumab may be indicated in these individuals [35].

# Clinical Practice Guidelines

## Recommendations:

1. Investigate patients with BCS and PVT for underlying local and systemic prothrombotic factors. Identification of one risk factor should not deter from looking for additional risk factors (A1)
2. Work-up consists of diagnosis for inherited and acquired thrombophilia factors, myeloproliferative neoplasms, paroxysmal nocturnal haemoglobinuria and autoimmune disorders (A1)
3. Investigate patients with both BCS and PVT for local risk factors, including intra-abdominal inflammatory conditions and abdominal malignancies (A1)
4. Thrombophilia screening should include protein S, protein C and antithrombin levels, FVL mutation, prothrombin G20210A gene variant and anti-phospholipid antibodies (APA). In case of APA positivity, this should be repeated after 12 weeks (A1)
5. Test for myeloproliferative neoplasms by testing for JAK2V617F mutation in SVT patients, and in individuals with normal peripheral blood cell counts (A1). In JAK2V617F mutation negative patients, calreticulin mutation screening should be performed and if both are negative, bone marrow histology should be considered. Patients have to be referred to a haematologist (B2)
6. Treat the underlying condition appropriately (B1). In case of an underlying MPN, anticoagulant treatment should be given indefinitely for SVT patients (B1)

## Budd-Chiari syndrome

BCS is defined as the obstruction of hepatic venous outflow that can be located from the small hepatic venules up to the entrance of the IVC into the right atrium [1]. Hepatic outflow obstruction related to cardiac disease, pericardial disease or sinusoidal obstruction syndrome (SOS) are excluded from this definition. BCS can be classified into: i) primary, caused by thrombosis in the absence of compression by space occupying lesions, or invasion by malignancy or parasites; and ii) secondary otherwise. Given the different therapeutic and prognostic implications, we will only discuss primary BCS. In Western countries pure hepatic vein thrombosis is most common [48], while in Asia a pure IVC or combined IVC/hepatic vein block predominates. The pathophysiological consequences include obstruction, which leads to sinusoidal congestion, ischemia, and finally hepatocellular necrosis. They can result in centrilobular fibrosis, nodular regenerative hyperplasia and/or cirrhosis.

### Clinical manifestations

Clinical presentation is heterogeneous and ranges from absence of symptoms to fulminant hepatic failure [1,49]. An asymptomatic presentation is often associated with the presence of large hepatic venous collaterals. In a multicentre prospective study of a large cohort of patients with BCS at diagnosis, ascites were present in 83% of patients, hepatomegaly in 67%, abdominal

pain in 61%, esophageal varices in 58% and gastrointestinal bleeding in 5% [2]. In approximately 15% of cases, BCS and PVT occur simultaneously [2,50]. Therapeutic options and prognosis tend to be worse in BCS-PVT patients [50].

Imaging studies display hepatic nodules in 60–80% of patients with BCS. They are usually benign and are the result of perfusion disturbances. Although, these nodules are characteristically small, in most cases under 4 cm in diameter, multiple (frequently more than 10 lesions), hypervascularized, and disseminated throughout the liver. A pathognomonic pattern is not detected on computed tomography (CT) or magnetic resonance (MR) imaging. Cumulative incidence of hepatocellular carcinoma (HCC) in BCS has been shown to be 4% (after a median follow-up of 5 years) [51], therefore differential diagnosis is essential. Biopsy has been suggested in patients with less than or equal to three nodules, nodules with a diameter more than or equal to 3 cm, heterogeneity or washout on the venous phase, changes in two consecutive imaging techniques, or increase in alpha-fetoprotein levels [51]. However, radiological and histological characterization of hepatic nodules in BCS cannot rely on the well-established criteria of HCC in cirrhosis and the only formal recommendation is close and careful multidisciplinary surveillance.

### Diagnosis

Diagnosis is established with unequivocal radiological confirmation of hepatic venous outflow obstruction. Doppler ultrasound has a diagnostic sensitivity of more than 75% and is the first line investigation [1]. If an experienced sonographer is not available, MR imaging and CT evaluation are used for diagnostic confirmation [1,48]. Venography is recommended if the diagnosis remains uncertain or for the characterization of anatomy prior to treatment. If imaging has failed to demonstrate obstruction of large veins then a liver biopsy can be used in order to assess small hepatic vein thrombosis.

### Treatment

The recommended stepwise therapeutic algorithm of BCS based on retrospective cohorts and prospective series of patients [2,52,53] is summarized in Fig. 1.

Patients with BCS have often required therapy for ascites and varices. These treatments should be administered following the same treatment recommendations as for ascites and portal hypertension in cirrhosis.

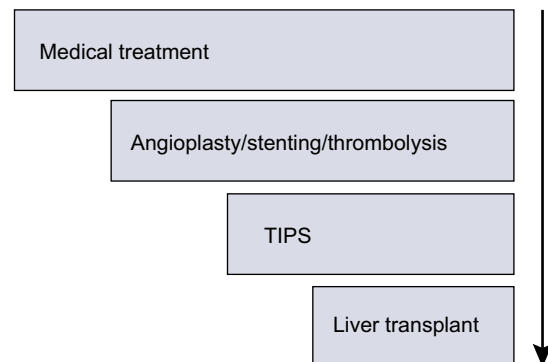


Fig. 1. Recommended stepwise therapeutic algorithm of Budd-Chiari syndrome.

Patients with BCS should receive anticoagulant therapy as soon as possible for an indefinite period of time in an attempt to reduce the risk of clot extension and new thrombotic episodes [1,2,52,54]. According to the recommendation for deep vein thrombosis, the patient should be treated with low molecular weight heparin (LMWH) for at least 5 to 7 days, and also with oral anticoagulant treatment with VKA, aiming at an international normalised ratio (INR) between 2 and 3. LMWH can be stopped when INR is within the target range for two consecutive measurements.

A high rate of bleeding complications while on anticoagulation (up to 50% of patients) has been reported in a cohort of BCS patients diagnosed between 1995 and 2005 [55]. In a more recent prospective cohort of patients diagnosed between 2005 and 2007, bleeding complications were less frequently observed (17% of patients), likely due to a better management of anticoagulation during invasive procedures or adequate prophylaxis for portal hypertension-related bleeding [53].

Treatment of the underlying prothrombotic cause (for instance MPNs) should be logically initiated concomitantly. Indeed, the benefits from early treatment for an underlying myeloproliferative disorder has been suggested in a retrospective cohort analysis [56].

The experience of correcting hepatic venous outflow obstruction with thrombolysis is limited. Good results have been reported in patients with recent and incomplete thrombosis treated with local and early infusion of a thrombolytic agent combined with angioplasty or stenting [57]. Complications however, can be fatal [58].

Partial or segmental stenoses are present in 60% of patients with IVC obstruction, and 25–30% of those with hepatic vein obstruction [59]. Angioplasty or stenting of these stenosis could re-establish the physiological drainage of portal and sinusoidal blood. Post-angioplasty re-stenosis is frequent but can be reduced when done in combination with a stent. Misplacement of a stent may compromise the subsequent performance of a transjugular intrahepatic portosystemic shunt (TIPS) or orthotopic liver transplantation (OLT). Overall angioplasty/stenting is the definitive treatment for less than 10% of Western BCS patients [53]. The efficacy may be greater in other regions of the world where there is a higher prevalence of this specific form of BCS [60].

Patients with BCS non-responsive to medical treatment or that are not candidates for angioplasty/stenting must be treated with derivative techniques. There is no clear explanation as to why some patients do not respond to medical treatment, therefore the characteristics of BCS patients' receiving TIPS differ from centre to centre. Some criteria have been proposed: clinical failure to therapy (treatment failure) was considered when criteria for complete or ongoing response were lacking [52]. Complete response was considered when all of the following six criteria were met and stable: (1) absence of clinically detectable ascites, with normal serum sodium and creatinine levels, in the absence of diuretic therapy, or on low dose diuretics (spironolactone 75 mg/d or furosemide 40 mg/d) and moderate NaCl intake; (2) increase in coagulation factor V to a level above 40% of normal value; (3) decrease in conjugated serum bilirubin to a level below 15 µmol/L; (4) absence of first or recurrent portal hypertension-related bleeding while on primary or secondary prophylaxis with non-selective beta blockers or with endoscopic therapy; (5) no occurrence of spontaneous bacterial infection; and (6) BMI >20 kg/m<sup>2</sup> after subtraction of ascites and edema. Ongoing

response was considered when all of the following three criteria were met on a 2-weekly evaluation basis: (1) in the presence of ascites, a negative sodium and water balance was achieved using low dose diuretics and moderate sodium intake, together with normal serum sodium and creatinine levels, or with increasing serum sodium if initially low and decreasing serum creatinine levels if initially high; (2) factor V level was increasing if initially low; and (3) serum conjugated bilirubin level was decreasing if initially high. These response criteria must be validated in future studies.

Derivative techniques, either surgical shunts or TIPS, are aimed to transform the portal system into an outflow tract [61]. The most frequent surgical shunt performed is the mesocaval shunt with a polytetrafluoroethylene (PTFE) stent or autologous jugular vein interposition. It is easier to do than the porto-caval side-to-side shunt when hypertrophy of the caudate lobe is present. Surgical shunts are ineffective if there is associated IVC thrombosis or severe compression of the IVC by an enlarged liver. In this situation some groups have performed a meso-atrial shunt or a cavo-atrial shunt plus a portocaval shunt. Surgical shunts have not demonstrated to be an independent survival advantage in cohorts of patients with BCS [62,63]. This is likely related to the high inherent mortality rate of the patient population with severe BCS, as well as to the high rate of dysfunction/thrombosis of the shunts [64–66]. On the other hand, TIPS has a lower morbidity and mortality rate than surgery and is feasible in most patients with IVC obstruction and in those with severe IVC stenosis. A recent multicentre retrospective European study including 124 BCS patients treated with TIPS showed excellent 1- and 5-year OLT-free survival (88% and 78%, respectively) [67]. These results have been confirmed by a recent prospective study [53]. PTFE-covered stents reduce the recurrence of post-procedure TIPS obstruction or dysfunction [53,67]. TIPS placement in patients with BCS requires special training. Indeed, in more than 45% of cases, a transcaval approach (direct puncture from the intrahepatic IVC) may be required due to complete thrombosis of the hepatic veins [67].

OLT in patients with BCS is associated with a survival [68] similar to that obtained in patients initially treated with TIPS [67]. It has been suggested that the placement of previous TIPS can make a posterior OLT more difficult if it is needed. However, this has not been confirmed in more recent studies [67,69]. BCS recurrence may occur after OLT. The incidence of this complication has markedly dropped since the initiation of early anticoagulation treatment after OLT and its lifelong maintenance. An exception for the need for anticoagulation could be in those patients whom the prothrombotic disorder is corrected by OLT (e.g. most inherited thrombophilia). The natural history of MPN must also be considered in the post-transplant course.

There are patients with severe BCS who may benefit from being treated directly with OLT, without previous use of TIPS. However, up until now there is no reliable method to identify such patients [53,67].

#### *Budd-Chiari and pregnancy*

Pregnancy in patients with BCS has an excellent maternal outcome provided patients have a well controlled disease. Fetal outcome is less favourable but it has been reported that pregnancies reaching week 20 of gestation are associated with an acceptable fetal prognosis even when 76% had preterm delivery [70]. VKA

## Clinical Practice Guidelines

are associated with a high risk of miscarriage and congenital malformations [71]. Therefore, a pregnancy test must be done as early as possible, if positive mothers should switch to LMWH [72] with periodic monitoring of anti-Xa activity.

### Prognosis

There have been various attempts to determine parameters or combinations of parameters that may predict prognosis in BCS patients [53,62,67,73]. Although all of these prognostic indices are valid for the assessment of transplant-free survival and invasive therapy-free survival, their predictive accuracy is suboptimal for use in individual patients in day to day clinical practice [74]. Development of HCC or progression of the haematological disease may modify prognosis of BCS.

### Recommendations:

1. Consider diagnosis of BCS in any symptomatic or asymptomatic patient with acute or chronic liver disease (**A1**)
2. Doppler ultrasound is the first line of investigation for BCS. MRI and CT have to be used for diagnostic confirmation (**A1**)
3. Reevaluate the patient with an expert radiologist in patients with negative imaging studies but a high suspicion of BCS (**A1**)
4. Refer patients with BCS to expert centres (**A1**)
5. Initiate therapy for complications of portal hypertension as recommended in patients with cirrhosis (**C2**)
6. Treat all BCS patients with anticoagulation, in the absence of major contraindications (**A1**). Portal hypertension complications, when adequately treated, are not a contraindication for anticoagulation (**B1**)
7. Consider brief interruption of anticoagulation therapy whenever an invasive procedure is performed, including paracentesis (**B1**)
8. Consider angioplasty/stenting as the first line decompressive procedure in patients with short hepatic vein stenosis or IVC stenosis (**A1**)
9. Closely monitor these patients for early detection of liver deterioration. Treat patients who do not respond to initial therapy, or do not respond to angioplasty/stenting with portal derivative techniques (**A1**). TIPS, using PTFE-covered stents, is the derivative treatment of choice (**A1**). Discuss surgical shunting when TIPS is not feasible or fails (**B1**)
10. Propose liver transplantation as a salvage treatment for patients in whom derivative techniques have failed (**A1**). Anticoagulation needs to be continued in most BCS patients after liver transplantation (**B1**)
11. Screen patients with BCS for HCC. Distinction between benign and malignant liver nodules is very difficult and may need referral to specialized centres (**A1**)

## Acute portal vein thrombosis (non-cirrhotic, non-malignant)

### Definition and scope

Acute PVT is defined as a recent formation of a thrombus within the portal vein and/or right or left branches. The thrombus may extend into the mesenteric or splenic veins; occlusion may be complete or partial. We will limit the discussion to acute PVT occurring in the absence of malignancy and cirrhosis [54,75]. Acute PVT may also occur in patients with long-standing obstruction of portions of the portal venous system [76].

### Manifestations

According to prospective [3] and retrospective studies [40,77,78], acute abdominal pain is present in 90% of acute PVT patients. A systemic inflammatory response syndrome is present in 85% of patients diagnosed with acute PVT which contrasts with local or systemic infection being present in only 20% of these patients. A significant number of patients only have mild non-specific symptoms so that the diagnosis is overlooked and PVT is recognised only at the stage of cavernomatous transformation. Liver tests generally show no, or only mildly and transient abnormalities. Ascites is present in 50% of patients; in most patients only visible on imaging [3]. Due to improved awareness and availability of sensitive non-invasive imaging, diagnosis of portal venous obstruction is now made in 50 to 70% of cases at the stage of acute PVT [76,78].

### Course and outcome

Intestinal infarction is the most concerning immediate complication of acute porto-mesenteric vein thrombosis, with a related mortality of up to 60%. Extensive bowel resection may be necessary with a risk of short bowel syndrome [79–82]. The incidence of intestinal infarction has currently declined to 2–20% in patients treated with anticoagulation [3]. In patients not receiving anticoagulation therapy, spontaneous recanalisation of symptomatic PVT appears to be exceptional [83].

Recognising venous mesenteric infarction is difficult as clinical, biological and radiological manifestations are non-specific. Persisting severe abdominal pain despite adequate anticoagulation, organ failure (shock, renal failure, metabolic acidosis, elevated arterial lactates), massive ascites and rectal bleeding all appear to be suggestive of infarction [79–82]. In a recent study, diabetes was the only factor independently associated with intestinal resection [84].

### Diagnosis

Doppler ultrasound is usually the first imaging procedure performed in the context of abdominal pain. It may detect an absence of flow within the portal vein. The presence of a hyper-echoic thrombus in the portal lumen may be lacking [43,85]. Doppler ultrasound, and MR have a lower sensitivity than CT imaging. Doppler ultrasound is dependent on the expertise and awareness of the operator [43,85]. Diagnosis and extension of acute portal venous obstruction should be confirmed by contrast enhanced CT and/or MR imaging. Acquiring images at the correct time (portal phase) is mandatory in order to prevent pitfalls.

Images acquired during the late arterial phase are not optimal for the diagnosis of PVT. Furthermore, in cases of low portal vein flow, a delayed arrival of contrast to the portal vein could be seen on CT, giving the appearance of a filling defect resulting in a false positive diagnosis of thrombosis [86].

Portal phase CT scan shows the absence of visible lumen corresponding to the portal vein clot; CT scan provides additional information regarding the extent of the thrombus to the mesenteric veins and arches, the presence of a local factor, or of congestion and ischemia of the bowel. Distal thrombosis (occlusion of second order radicals of superior mesenteric vein), anomalies of the bowel (homogeneous or heterogeneous hypoattenuating or hyperattenuating wall thickening, dilatation, abnormal or absent wall enhancement) or of the mesentery, mesenteric stranding, large ascites, pneumatosis, and portal venous gas are more frequently observed in patients who will need intestinal resection [84].

Studies addressing the duration of PVT are scarce. A recent thrombus can be defined as a thrombus occurring in the setting of abdominal pain and or systemic inflammatory response syndrome. A spontaneous hyperdense clot in the portal vein lumen on a non-enhanced CT scan may suggest that the thrombus dates back to less than 30 days after onset of symptoms [43]. Absence of portal cavernoma is also of help, although cavernoma may not develop in unilateral portal branch obstruction. A cavernoma may be identified as early as 15 to 30 days after the apparent onset of abdominal pain [43]. Furthermore, acute thrombosis may superimpose on a long-standing cavernoma.

Underlying prothrombotic disorders and local factors are common in adults. These disorders constitute major determinants of outcome, and may require specific therapy (see section 1). In children, aetiological investigations have been negative or only show common weak prothrombotic conditions [87].

### Therapy

The aim of therapy for acute PVT is; i) to prevent the extension of thrombosis to mesenteric veins and thereby, mesenteric venous infarction; and ii) to achieve portal vein recanalisation (Fig. 2) [43,85].

### Anticoagulation

In a recent prospective study, thrombus extension was prevented in all patients who had early initiation of anticoagulation therapy [3]. Only 2/95 cases of limited intestinal infarction were observed, although 60% of patients had initial involvement of the superior mesenteric vein. Furthermore, recanalisation of the portal, splenic and superior mesenteric veins was obtained in 39%, 80%, and 73% of anticoagulated patients, respectively. Recanalisation of the portal vein did not occur in any of the patients beyond the sixth month of anticoagulation treatment. These findings independently validated retrospective single centre studies [3,40,77,78]. Bleeding while on anticoagulation occurred in 9% of patients. Mortality rate was 2% and was not related to bleeding or PVT [3]. Among baseline factors, splenic vein obstruction and ascites [3] and delay in initiating anticoagulation [77] have been associated with the absence of recanalisation of the portal vein. These findings need further confirmation in other cohorts.

In most previous studies, anticoagulation therapy was mainly based on unfractionated heparin or LMWH or derivatives at high

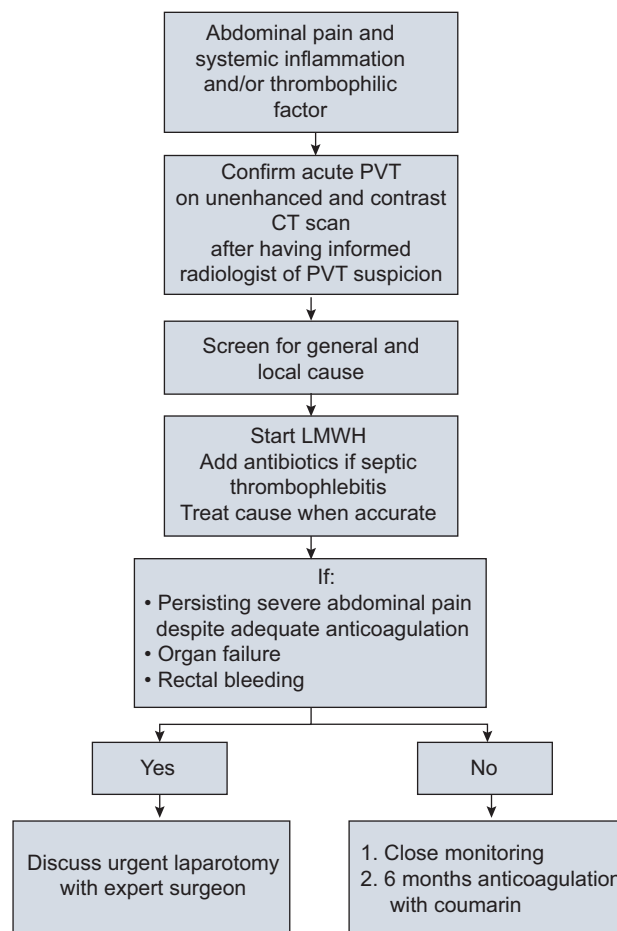


Fig. 2. Proposed algorithm for the management of acute portal vein thrombosis.

so-called therapeutic doses. In the most recent prospective European study, unfractionated heparin and LMWHs have been used in 25% and 65% of patients, respectively [3]. In most studies LMWH has been substituted for VKA targeting an INR between 2 and 3.

Heparin-induced thrombocytopenia (HIT) has been found to occur in up to 20% of PVT patients treated with unfractionated heparin, a much higher rate compared to HIT in patients without PVT [88]. The incidence is probably lower in patients treated with LMWH.

### Thrombolysis

The experience of local thrombolysis, either venous or arterial, has been reported in no more than 100 patients, mainly as case reports. The transhepatic route or transjugular routes have been used. The reported recanalisation rates have been similar to those achieved with anticoagulation alone. However, 50% of treated patients developed major procedure-related bleeding, with a fatal outcome in some [58,89,90]. The transjugular approach for thrombolysis appears to be associated with reduced complications but the data remains limited to less than 30 treated patients [91,92]. With surgical thrombectomy, recanalisation is achieved

## Clinical Practice Guidelines

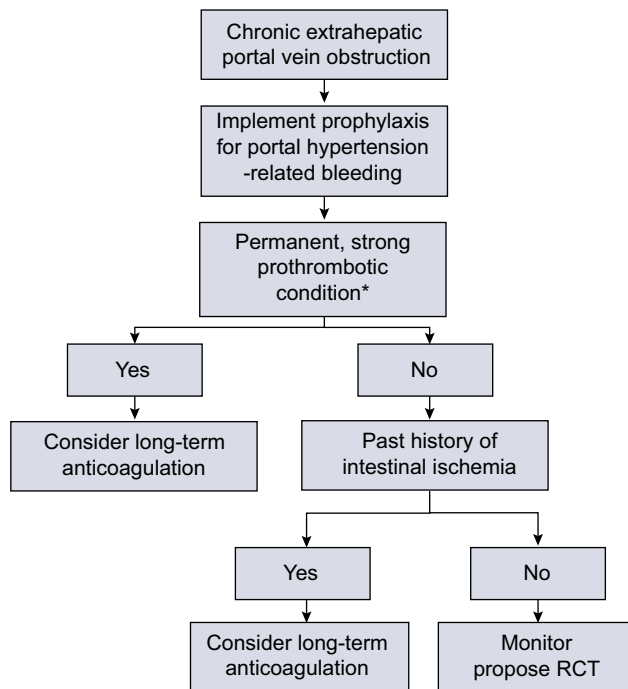
in only 30% of the patients. It is associated with a high recurrence rate, when performed >30 days from apparent onset [93]. Recently it has been shown that balloon angioplasty and/or stent placement without thrombolysis or thrombectomy may be a safe and effective treatment modality for post-operative main portal vein and superior mesenteric vein thrombosis [94]. As the long-term outcome of patients with chronic PVT is generally good (five-year survival rate above 70%) and mostly related to the associated conditions, the risk: benefit balance of such invasive procedures have to be considered [95].

### Antibiotics

When septic pylephlebitis is diagnosed, prolonged treatment with antibiotics adapted to isolated bacteria or to anaerobic digestive flora is necessary [96].

### Prognosis

Recanalisation of the portal vein must be expected to occur up to 6 months whereas recanalisation of mesenteric and splenic veins steadily increase until 12 months follow-up [3]. Over half of the patients (55%) not achieving recanalisation will develop gastroesophageal varices during their follow-up, with a two-year actual probability of variceal bleeding of 12% and 16% for ascites [77]. Severe portal biliopathy, detected during imaging studies, developed in 30% of patients with acute PVT within 1 year [97].



**Fig. 3. Proposed algorithm for making a decision of permanent anticoagulation in patients with chronic extrahepatic portal vein obstruction.** Assessment based on personal and familial history of unprovoked deep vein thrombosis, and on findings of isolated or combined prothrombotic conditions.

### Recommendations:

1. Consider the diagnosis of acute portal vein obstruction in any patient with abdominal pain (A1)
2. Use Doppler ultrasound as the first line investigation for acute PVT. Use CT for diagnostic confirmation and the assessment of extension (A1)
3. Establish or rule out underlying cirrhosis or obliterative portal venopathy (C1)
4. Consider intestinal infarction in patients with persisting severe abdominal pain, rectal bleeding, moderate or massive ascites, or multiorgan dysfunction. Closely monitor these patients for signs of deterioration (B1)
5. Initiate immediate anticoagulation with LMWH in the absence of major contraindications to anticoagulation (A1)
6. Screen for HIT in patients with a sudden unexplained platelet count fall  $\geq 50\%$  or to a value less than  $150 \times 10^9/L$ , especially in those in whom unfractionated heparin was initiated (A1)
7. According to recommendations for venous thromboembolism, initial treatment should be with LMWH, in addition, anti-Xa activity should be monitored in overweight patients, pregnancy, and poor kidney function, targeting a level between 0.5 and 0.8 IU/ml (A1). Oral VKA are used for long-term anticoagulant treatment targeting an INR between 2 and 3 (B1)
8. Anticoagulation therapy should be given for at least 6 months (A1)
9. Perform a CT scan to assess recanalisation of the portal venous system at 6-12 months follow-up (B1)
10. Screen for gastroesophageal varices in unre canalised patients (A1)
11. Perform MR imaging cholangiography in patients with persisting cholestasis or biliary tract abnormalities suggestive of portal biliopathy (B2)

### Extrahepatic portal vein obstruction (non-cirrhotic, non-malignant)

Extrahepatic portal vein obstruction (EHPVO) occurs due to the three following mechanisms; malignant invasion (frequently but improperly referred to as malignant thrombosis), portal vein narrowing within a malignant tumor, and thrombosis. Malignant invasion and portal vein narrowing will not be discussed further in this section. Following acute thrombosis, in the absence of recanalisation, the portal venous lumen obliterates and porto-portal collaterals develop. This process is called cavernomatous transformation of the portal vein, the result of which is the portal cavernoma, which fully develops in a couple of months after acute thrombosis. Chronic PVT has been used to designate the

latter condition although these terms are not as factual as cavernoma or cavernomatous transformation. There is a debate as to whether portal cavernoma may result from other mechanisms than thrombosis. In children, aetiological investigation has been negative or has shown only weak common prothrombotic conditions [98]. When a cavernoma is found in infancy or childhood in the absence of local or general factors for thrombosis, the hypothesis of a congenital malformation cannot be ruled out although evidence for this hypothesis is still poor [98].

#### Manifestations

Available data in patients with non-cirrhotic non-malignant EHPVO come from short-term prospective studies following acute thrombosis [3], or from retrospective cohort studies where patients have received various forms of treatment [40,42,76,99]. Due to the improved sensitivity of non-invasive imaging, diagnosis of EHPVO is increasingly being made at an early stage of acute PVT [40,42,76,99]. Among features of portal hypertension, gastrointestinal bleeding has become a rare mode of presentation, by contrast with frequent fortuitous findings of an enlarged spleen, reduced blood cell counts, gastroesophageal varices or portal hypertensive gastropathy, or portosystemic collaterals at abdominal imaging [40,42,76,99]. The severity of portal hypertension typically contrasts with a mild or absent liver dysfunction and with normal levels of transaminases, alkaline phosphatase, and gamma-glutamyl transferase. Some patients may experience post-prandial abdominal pain, or features of incomplete bowel obstruction related to ischemic stenosis. Less frequently, initial manifestations are with biliary symptoms (biliary pain, pancreatitis, cholecystitis) related to portal cholangiopathy, a condition characterized by compression and deformation of intra- and extrahepatic bile ducts by the collateral veins constituting the cavernoma. Progressive cholestatic disease or recurrent bacterial cholangitis are rare in patients with portal cholangiopathy [42,76,99].

#### Outcome

The most frequent complication is gastrointestinal bleeding related to portal hypertension [40,42,76,99], followed by recurrent thrombosis (mostly in the splanchnic area) [40,42,76,99] and more rarely, biliary complications [100]. Asymptomatic recurrent thrombosis in the splanchnic area is underestimated and its actual clinical significance requires further evaluation. Ascites, bacterial infections and overt encephalopathy are uncommon except following an episode of gastrointestinal bleeding [101]. Subclinical encephalopathy appears to be much more common than previously suspected [102]. In children, a specific additional consequence appears to be growth failure [103]. Regenerative macronodules may develop but HCC has not been reported yet [104]. Previous gastrointestinal bleeding and size of esophageal varices have been identified as independent predictors for gastrointestinal bleeding [40,42]; the presence of an underlying prothrombotic condition as a predictor for recurrent thrombosis [40,42]; dilated segments of the bile ducts, for clinical biliary complications [97]; and age, ascites, extension to the superior mesenteric vein and severity of underlying conditions as predictors for death [40,42,76,99].

#### Diagnosis

The diagnosis of EHPVO should be considered in patients with features of portal hypertension or hypersplenism; in patients affected with a condition associated with a risk for PVT (general: myeloproliferative neoplasm, antiphospholipid syndrome, inherited thrombophilic factors, or local: pancreatitis, diverticulitis, inflammatory bowel disease); in patients with abdominal pain; and in patients with biliary disease. Rarely, the diagnosis has to be considered in a context resembling decompensated cirrhosis (encephalopathy, and/or ascites, and/or bacterial infection).

A diagnosis of EHPVO is based on the findings of Doppler ultrasound, and axial CT or MR imaging using vascular contrast agents. The experience and awareness of the radiologist is crucial. Essential features are; (a) the absence of visible lumen corresponding to the portal vein; and (b) the presence of numerous, serpiginous vascular channels in porta hepatis [105,106]. Other less specific features may provide indirect clues for an obstructed portal vein: a dysmorphic liver where segment 1 and segment 4 are enlarged but surface is smooth; a mosaic pattern of parenchymal enhancement in the arterial phase, with homogeneous enhancement at a later phase; an increased enhancement of the peripheral parts of the liver at the arterial phase; a dilated hepatic artery; and a mild irregular dilatation of the bile ducts [107]. A thickened gallbladder wall due to collateral veins should be differentiated from cholecystitis. A thickened heterogenous pancreas due to collateral veins should be differentiated from pancreatic cancer and chronic pancreatitis. In cases of pure portal vein obstruction, liver biopsy shows an essentially normal liver. However, a cavernomatous transformation of the portal vein can be superimposed on cirrhosis or obliterative portal venopathy where diagnosis requires a liver biopsy [3,99]. Liver biopsy in EHPVO is indicated in patients with persistently abnormal liver tests or a dysmorphic liver whose aspect is not typical for extrahepatic venous obstruction as described above. Non-invasive tests like elastometry would be most useful in recognising underlying liver disease [108].

Underlying prothrombotic disorders and local factors are common in adults. These disorders constitute major determinants of outcome, and may require specific therapy (Fig. 3).

#### Therapy

##### *Prevention of thrombotic extension or recurrence*

The effect of specific treatments for underlying conditions has not been evaluated. Evidence for a favourable benefit/risk ratio of anticoagulation is low as no prospective study has ever been performed. In three retrospective cohort studies on non-cirrhotic PVT patients, long-term anticoagulation has been associated with a reduced risk of recurrent thrombosis. In a multivariate analysis it was found to be independent factor in one study (risk ratio 0.39,  $p = 0.02$ ) [42] and borderline in the other (hazard ratio 0.2,  $p = 0.1$ ) [41]. Prevention of rethrombosis was also observed at univariate analysis in a large cohort of patients whose initial presentation was with abdominal pain or intestinal ischemia [40]. When evaluated in patients with EHPVO receiving anticoagulation, the risk of recurrent bleeding has not been shown to be increased in the context where prophylaxis for bleeding has been routinely performed [40,42]. In another study where the strategy for bleeding prophylaxis has not been evaluated, anticoagulation therapy was significantly associated with an increased risk of

## Clinical Practice Guidelines

bleeding [41]. The severity of bleeding on anticoagulation has been found to be similar in patients with and without anticoagulation at the time of bleeding [42]. Multivariate analysis indicated a favourable impact of anticoagulation therapy on survival with a statistically significant decrease in mortality in one study [99], and a non-significant decrease in the other [41]. Extrapolation of these data collected between 1983–1998 [83], 1973–2005 [84] and 1985–2009 [41] requires caution.

### Prevention of the complications of EHPVO

In most available surveys, patients have been treated for portal hypertension according to the recommendations for patients with cirrhosis. Hemodynamic data in animals with pre-hepatic portal hypertension [109] and in patients with non-cirrhotic portal hypertension [110] indicate beneficial effects of non-selective beta adrenergic blockade on splanchnic haemodynamics. Theoretical deleterious effects of non-selective beta blockers on patients with extended thrombosis promoting abdominal pain or intestinal ischemia have never been proved.

According to multivariate analysis, beta adrenergic blockade decreases the risk of bleeding in patients with large varices [42], and improves survival in patients with chronic portomesenteric venous obstruction [99]. Sclerotherapy reduces the incidence of bleeding in previously untreated patients. Endoscopic variceal band ligation is superior to sclerotherapy according to a short-term randomized controlled trial in children [111]. In children, combination of ligation and sclerotherapy provides marginal advantage to either band ligation alone or sclerotherapy alone. In adults, by two years of follow-up, there was no difference in the rate of recurrent bleeding between treatment with propranolol or with band ligation for non-cirrhotic portal hypertension (including a majority of patients with EHPVO) [112]. In the latter study, none of the patients were receiving anticoagulation. Rebleeding rate was about 20% at two years.

In selected patients, low mortality and rebleeding rates have been observed with surgical portosystemic shunting using superior mesenteric or splenic veins [113]. However, the proportion of patients where these shunts are feasible remains unclear. The data with TIPS are still extremely limited in patients without cirrhosis or malignancy. While covered TIPS insertion appears to be feasible when intrahepatic portal veins are visible, results are available only on a short-term follow-up (average 18 months) [114]. Encephalopathy appears to occur at a similar rate as in patients with cirrhosis.

In children with patent superior mesenteric and left portal veins, a bypass can be constructed between these two veins (so-called mesenterico-Rex shunt). The feasibility and long-term patency appears to be high. Gastrointestinal bleeding is effectively prevented. An improvement in mental status and in coagulation factor levels as been observed [115,116]. There is no report of adult patients treated with mesenterico-Rex shunt.

Only patients with clinical manifestations of portal cholangiopathy should be considered for a specific treatment [100]. Bile stones should be treated endoscopically. Risk of endobiliary maneuvers is haemobilia from ruptured intrabiliary varices, which can be massive. Biliary stricture associated with jaundice or bile stones can also be treated endoscopically with repeated stenting. When superior mesenteric vein or splenic veins are evident a surgical shunt can be considered. Because of anecdotal reports of successful TIPS placement, such a procedure can also be considered although results beyond a few months of follow-up have not been reported [114,117].

### Overall outcome

Overall outcome is relatively good in patients with extrahepatic PVT in the absence of cirrhosis or malignancy. Five-year survival rates above 70% have been reported in large cohorts spanning over the last 20 years [40–42,76,99]. No comparison with the general population is available.

### Recommendations:

1. Consider the diagnosis of extrahepatic portal vein obstruction (EHPVO) in any patient presenting with features of portal hypertension, hypersplenism or abdominal pain, or biliary tract disease (**A1**)
2. Consider screening for extrahepatic portal vein obstruction in patients with myeloproliferative disease and antiphospholipid syndrome (**B2**)
3. Use Doppler ultrasound as first line investigation for the diagnosis of EHPVO. Use CT for diagnostic confirmation and extension assessment (**A1**)
4. Rule out underlying cirrhosis or obliterative portal venopathy whenever liver tests are abnormal, a cause for chronic liver disease is present, or the liver is dysmorphic, or results of liver elastometry are abnormal (**C1**)
5. Perform MR imaging cholangiography in patients with persisting cholestasis or biliary tract abnormalities suggesting occurrence of portal biliopathy (**B2**)
6. Manage portal hypertension according to the guidelines elaborated for cirrhosis (**B1**)
7. Once prophylaxis for gastrointestinal bleeding has been implemented:
  - a. Treat underlying prothrombotic conditions according to corresponding guidelines (**B1**)
  - b. Consider permanent anticoagulation in patients with a strong prothrombotic condition, or past history suggesting intestinal ischemia or recurrent thrombosis on follow-up (**B2**)
  - c. Long-term anticoagulation is indicated in case of an underlying MPN (**B1**)

## Idiopathic non-cirrhotic portal hypertension

### Introduction

Many disorders are associated with non-cirrhotic intrahepatic portal hypertension, such as infiltrative diseases, vascular malignancies, schistosomiasis, congenital hepatic fibrosis and sarcoidosis [118]. The diagnosis of idiopathic non-cirrhotic portal hypertension (INCPH) can be made if all these disorders have been excluded and consequently no clear liver disease has been identified (Table 3). The nomenclature of this condition is ambiguous and it has been referred to as hepatoportal sclerosis, non-cirrhotic portal fibrosis, idiopathic portal hypertension, incomplete septal cirrhosis and nodular regenerative hyperplasia

**Table 3. Diagnostic criteria of idiopathic non-cirrhotic portal hypertension.\***

1) Clinical signs of portal hypertension (any one of the following**)
Splenomegaly/hypersplenism
Esophageal varices
Ascites (non-malignant)
Minimally increased hepatic venous pressure gradient
Portovenous collaterals
2) Exclusion of cirrhosis on liver biopsy
3) Exclusion of chronic liver disease causing cirrhosis or non-cirrhotic portal hypertension†
Chronic viral hepatitis B/C
Non-alcoholic steatohepatitis/alcoholic steatohepatitis
Autoimmune hepatitis
Hereditary hemochromatosis
Wilson's disease
Primary biliary cirrhosis
4) Exclusion of conditions causing non-cirrhotic portal hypertension
Congenital liver fibrosis
Sarcoidosis
Schistosomiasis
5) Patent portal and hepatic veins (doppler ultrasound or computed tomography scanning)

\*All criteria must be fulfilled in order to diagnose INCPH. \*\*Splenomegaly must be accompanied by additional signs of portal hypertension in order to fulfil this criterion. †Chronic liver disease must be excluded since severe fibrosis might be understaged on liver biopsy.

[119]. Agreement on a uniform nomenclature is an essential requirement. Since the focus of the current guideline is on vascular liver disease, we restrict our recommendations for INCPH which is thought to be caused largely by parenchymal vascular obstruction, while other forms of non-cirrhotic intrahepatic portal hypertension are associated with a large group of distinct liver diseases and presumably have less of a vascular etiology [118]. Thrombophilia, immunological disorders, specific medication (e.g. azathioprine and didanosine) and infections (e.g. HIV infection) have been identified as the major potential causes for portal venous obliteration [120,121]. In Western INCPH patients, a 40% prevalence of thrombophilic disorders has been reported [120].

#### Clinical presentation

Clinical presentation is dependent on referral patterns and on the medical specialist who makes the diagnosis (e.g. hepatologist vs. haematologist). In large studies from India the majority of patients present with gastrointestinal haemorrhage related to portal hypertension. This is most commonly due to esophageal varices, although gastric varices and portal hypertensive gastropathy can occur in a minority. Commonly, and more often than in other causes of portal hypertension (e.g. liver cirrhosis and PVT), a large spleen is observed in patients with INCPH [120,122]. At initial diagnosis, patients present mainly with normal liver function [120–122]. Only a minority demonstrate impaired liver function, mainly in the context of intercurrent conditions. The presence of ascites may be associated with poor survival [121]. Hepatic encephalopathy has been rarely reported but can be found due to massive portosystemic shunting [123].

#### Diagnosis

Diagnosis of INCPH remains a challenge because there is no single test that can be regarded as a gold standard. Patients with INCPH are often radiologically misclassified as cirrhotic since abdominal ultrasonography in these patients demonstrates liver surface nodularity and thickening of portal vein walls in combination with signs of portal hypertension [120,121]. A clue for the correct non-invasive diagnosis of INCPH might be low liver stiffness measurement by transient elastography (<12 kPa) [108,124]. A recent study demonstrated metabolomic analysis as a potential tool for the diagnosis of INCPH [125].

In order to exclude severe fibrosis or cirrhosis, liver histology remains essential in the diagnosis of INCPH. Macroscopical examination often reveals organised thrombi in the large portal vein branches, liver surface nodularity, and liver dysmorphism [126]. In the past, INCPH has been classified morphologically into four different categories: idiopathic portal hypertension (equivalent to hepatoportal sclerosis or non-cirrhotic portal fibrosis), nodular regenerative hyperplasia, partial nodular transformation and incomplete septal cirrhosis [119]. However, since all these entities share histopathological characteristics (obliterative vascular lesions), it has been suggested that INCPH can be viewed as a distinct single entity with various pathological aspects, rather than different clinicopathological entities [118]. The most prevalent histological features observed in INCPH patients are phlebosclerosis, nodular regeneration, sinusoidal dilatation, para-portal shunt vessels and perisinusoidal fibrosis [120,121,127]. Phlebosclerosis is generally regarded as the primary lesion in the development of the intrahepatic haemodynamic changes [128]. Potentially this obliteration of portal venules results in disturbed intrahepatic circulation and subsequently parenchymal remodeling (nodular regeneration). In order to demonstrate the presence of these lesions, large liver specimens containing a sufficient amount of portal tracts are needed (transjugular specimens often are too small). Nevertheless, a sufficient specimen size can show normal liver histology in liver biopsies from INCPH patients.

#### Natural history

Mortality by variceal haemorrhage in INCPH is significantly lower than that observed in cirrhotic patients, likely because of a preserved liver function [118]. In comparison to patients with cirrhosis a higher incidence of PVT has been reported in patients with INCPH [120,121,129]. Starting early anticoagulation therapy leads to recanalisation in 54% of patients [129]. A minority of patients develop liver failure over time, which might even necessitate a liver transplantation [121,123]. A poor outcome can be implicated by a precipitating factor or an additional cause for liver damage [120]. Liver function impairment and ascites in these patients can possibly be explained by a reduction in portal flow and subsequently atrophy of the peripheral hepatic parenchyma. Despite low liver-related mortality, overall survival in INCPH patients is lower than generally considered as a result of high mortality related to INCPH associated disorders [121].

#### Treatment

##### Treatment and prophylaxis of variceal gastrointestinal bleeding

Data on management or prophylaxis of variceal bleeding and INCPH are lacking [118]. Endoscopic therapy has been found to

## Clinical Practice Guidelines

be effective in controlling acute variceal bleeding in 95% of the INCPH patients [130]. No data has yet been published regarding endoscopic band ligation in these patients. However, considering the superiority of ligation in patients with cirrhosis or EHPVO, applying this treatment in INCPH patients with varices is preferable. With uncontrolled bleeding, portal systemic shunting by insertion of TIPS should be considered. Although there is literature from India on emergency surgical shunting, this is currently not regarded to be superior to TIPS insertion, which is less invasive. Complications of portosystemic shunting such as hepatic encephalopathy are rare due to the preserved liver function in most of the patients [121]. Endoscopic therapy has been shown to reduce the risk of variceal rebleeding in patients with INCPH [131]. Data are lacking regarding the efficacy of non-selective beta blockers in the setting of INCPH, however in keeping with the good results of bleeding prophylaxis in the setting of cirrhosis we recommend to use the same approach in INCPH patients.

### Anticoagulation

Anticoagulation therapy has been proposed by several investigators to prevent disease progression and to maintain portal vein patency [120,132]. However, considering the fact that gastrointestinal bleeding is the main complication and the role of thrombophilia in the pathogenesis is uncertain, this treatment is still debated and cannot be generally recommended. Anticoagulation can only be considered in patients with INCPH with clear underlying prothrombotic conditions or in patients who develop PVT.

### Liver transplantation

Several reports describe liver transplantation in the setting of INCPH [120,121,123]. The indications for liver transplantation are unmanageable portal hypertension-related complications and progressive liver failure.

### Recommendations:

1. Consider the diagnosis of INCPH in any patient with portal hypertension particularly when there is no other cause for liver disease (**B1**)
2. INCPH diagnosis requires the exclusion of cirrhosis and other causes of non-cirrhotic portal hypertension (**B1**)
3. Perform liver biopsy for the diagnosis of INCPH (**A1**)
4. Manage portal hypertension according to the guidelines elaborated for cirrhosis (**B1**)
5. Screen, at least every 6 months, for the occurrence of PVT (**B1**)
6. Liver transplantation has to be considered in INCPH patients that develop liver failure, or unmanageable portal hypertension-related complications (**B1**)

## Hepatic vascular malformations in hereditary haemorrhagic telangiectasia

### Definition

Hereditary haemorrhagic telangiectasia (HHT), or Rendu-Osler-Weber disease, is a genetic disorder with autosomal dominant inheritance, characterized by widespread cutaneous, mucosal and visceral telangiectasias and is reported to affect 1–2/10,000 people in the general population [133]. The clinical presentation of HHT varies widely based on the number, type and location of the telangiectasias or larger vascular malformations (VMs). The clinical criteria for HHT diagnosis, known as the Curaçao criteria, have been established by a panel of experts (Table 4): the diagnosis of HHT is certain with three criteria, likely with two, and unlikely with one or no criteria [134]. Most patients have mutations in one of the two known disease-related genes: *endoglin* (*ENG*, on chromosome 9, HHT1) and *activin A receptor type II-like 1* (*ACVRL1*, on chromosome 12, HHT2), both of which are involved in the TGF $\beta$  pathway. Mutations in the

**Table 4. Diagnostic criteria of HHT – Doppler ultrasound grading of liver VMs.**

HHT - Curaçao Clinical Criteria	Description
Epistaxis	Spontaneous and recurrent
Telangiectases	Multiple, at characteristic sites: lips, oral cavity, fingers, nose
Visceral lesions	Gastrointestinal telangiectasia, pulmonary, hepatic, cerebral or spinal Arterio-Venous malformations
Family history	A first degree relative with HHT according to these criteria
Liver VMs in HHT- Doppler ultrasound grading	
0+	<ul style="list-style-type: none"> <li>• Hepatic Artery diameter &gt;5 &lt;6 mm , and/or</li> <li>• Peak Flow Velocity &gt;80 cm/sec, and/or</li> <li>• Resistivity Index &lt;0.55, and/or</li> <li>• Peripheral hepatic hypervascularization</li> </ul>
1	<ul style="list-style-type: none"> <li>• HA dilatation, only extrahepatic &gt;6 mm, and</li> <li>• PFV &gt;80 cm/sec, and/or</li> <li>• RI &lt;0.55</li> </ul>
2	<ul style="list-style-type: none"> <li>• HA dilatation, extra- and intrahepatic, PFV &gt;80 cm/sec</li> <li>• Possibly associated with moderate flow abnormality of hepatic and/or portal veins</li> </ul>
3	<ul style="list-style-type: none"> <li>• Complex changes in hepatic artery and its branches, with marked flow abnormalities</li> <li>• Abnormality of hepatic and/or portal vein flow</li> </ul>
4	Decompensation of arteriovenous shunt with: <ul style="list-style-type: none"> <li>• Dilatation of hepatic and/or portal vein</li> <li>• Marked flow abnormalities in both arteries and vein/s</li> </ul>

*SMAD4* gene can cause a rare syndrome combining juvenile polyposis and HHT; recently additional genes have been found on chromosome 5 and 7 [133]. Genetic testing is available on a clinical basis.

*Hepatic VMs in HHT*

Hepatic VMs are found in 44–74% of HHT-affected subjects [135,136], implying a prevalence in the general (non-HHT) population varying between 1/7000 to 1/12,500. The prevalence of hepatic VMs depends substantially on HHT genotype, with greater frequency of hepatic VMs in HHT2 genotype than in HHT1 genotype [137,138]. The penetrance of most of the clinical features of HHT depends on the patient's age, with a mean age of patients with hepatic VMs of 52 years [139]. Previous data shows a strong and significant predominance of hepatic VMs in females who have HHT, both for asymptomatic and symptomatic lesions, with a male/female ratio varying from 1:2 to 1:4.5; therefore, the expression of HHT in the liver is likely dependent on the patient's sex [135,137].

*Pathogenesis*

Hepatic VMs unique to HHT involve the liver diffusely and evolve in a continuum from small telangiectases to large arteriovenous malformations, 21% of patients show an increased size of liver VMs and complexity over a median follow-up of 44 months [135].

Three different and often concomitant types of intrahepatic shunting (hepatic artery to portal vein, hepatic artery to hepatic vein and/or portal vein to hepatic vein) can lead to different but possibly coexistent clinical features: high-output cardiac failure (HOCF), portal hypertension (PH), encephalopathy, biliary ischemia, and mesenteric ischemia, the latter two being due to a blood flow steal through arteriovenous shunting. Perfusion abnormality can also entail hepatocellular regenerative activity, either diffuse or partial, leading to focal nodular hyperplasia (FNH), which has a 100-fold greater prevalence in HHT patients than in the general population, or to nodular regenerative hyperplasia [140–143].

*Clinical presentations*

Only 8% of patients with liver VMs are symptomatic in cross-sectional surveys [136,139]. A recent cohort study with a median follow-up of 44 months has shown that hepatic VM-related morbidity and mortality will occur in 25% and 5% of patients respectively, with incidence rates of complications and death 3.6 and 1.1 per 100 person-years, respectively. The clinical outcome of liver VMs correlates with their severity [135].

HOCF represents the predominant complication associated with HHT [142,143], but complicated PH occurs at a rate comparable to that of HOCF (1.4 and 1.2 respectively per 100 person-years); HOCF and complicated PH each accounts for about a half of hepatic VM-associated fatalities. In patients with chronic cardiac overload due to liver VMs atrial fibrillation occurred at a 1.6 rate per 100 person-years, suggesting that this arrhythmia in patients with liver VMs is not purely coincidental and should be approached with special caution [135].

PH due to arterioportal shunts can manifest itself with severe recurrent variceal bleeding; however both a case series and a cohort study have shown that gastrointestinal bleedings in patients with liver VMs were more often due to bleeding from gastrointestinal telangiectasias than to variceal bleeding [135,140].

Anicteric cholestasis is observed in one-third of patients with liver VMs [135]; its degree is generally correlated with the severity of vascular malformations.

Much rarer presentations of liver VMs in HHT are encephalopathy, mesenteric angina, or ischemic cholangiopathy with potential hepatic necrosis [135,140,142–145].

*Diagnosis*

Screening for hepatic VMs with Doppler ultrasound in asymptomatic individuals with suspected or certain HHT has been recommended because a correct diagnosis can help to clarify the diagnosis of HHT and improve subsequent patient management [142,143].

The diagnosis of liver involvement in HHT requires laboratory assessment and sensitive imaging methods such as abdominal Doppler ultrasound or abdominal CT [136,139]. Doppler ultrasound has been proposed as the first line investigation for the assessment of liver VMs taking into account its safety, tolerability, low costs, accuracy for the detection of liver VMs [139,146] and good interobserver reproducibility [147]. Furthermore, Doppler ultrasound is the only imaging technique which can give a severity grading (from 0.5 to 4) (Table 4) of liver VMs which correlates with clinical outcome and allows a tailored patient management and follow-up [135].

Echocardiographic evaluation of cardiac function and morphology, particularly cardiac index and systolic pulmonary arterial pressure, gives a non-invasive estimate of the haemodynamic impact of liver VMs [148].

Further testing (either one or a combination of the following: gastrointestinal endoscopy, CT, MR, angiography, cardiac catheterisation, portal pressure measurement with hepatic venous pressure gradient) may be required depending either on the presence of focal liver lesions or on the severity of liver VMs and their haemodynamic impact.

Characterization of a liver mass in the context of HHT can be made non-invasively by evaluating epidemiological (and namely the high prevalence of FNH in HHT), clinical and laboratory data (including serological tumor markers, hepatitis B and C markers) as well as imaging (at least two examinations – whether Doppler ultrasound, MR or CT – showing suggestive findings). Liver biopsy is thus not necessary and should be regarded as risky in any patient with proven or suspected HHT, considering the reported high prevalence of liver VMs in HHT [142,143].

Diffuse liver VMs are unique to HHT and their presence should always lead to the search of HHT diagnostic criteria. Other much rarer syndromes, such as Klippel-Trénaunay-Weber syndrome, can be associated to liver VMs. Multiple FNH, or, to a lesser extent, hypervascular metastases can cause enlargement of hepatic artery. The association of history, clinical and imaging findings together with the absence of other criteria for HHT will assist the correct diagnosis.

# Clinical Practice Guidelines

## Treatment

Currently, no treatment is recommended for asymptomatic liver VMs. Patients with symptomatic liver VMs require intensive medical treatment either for HOCF (salt restriction, diuretics, beta blockers, digoxin, angiotensin-converting enzyme inhibitors, antiarrhythmic agents, cardioversion and radiofrequency catheter ablation), or for complications of PH and encephalopathy (as recommended in cirrhotic patients), or for cholangitis (antibiotics) [142,143]. Supportive care is also important in these patients, either as blood transfusions or iron administration for anemia and treatment of the source of bleeding (either epistaxis or gastrointestinal bleeding) in actively bleeding patients.

Of note, 63% of patients show a complete response, and a further 21% a partial response to therapy for complicated liver VMs [135]. This high response rate argues for the importance of an intensive approach to symptomatic liver VMs and for a cautious approach to major remedies.

For patients failing to respond to an initial intensive medical therapy, invasive treatments, including transarterial embolization of liver VMs or OLT, are considered. There is sparse literature which suggests that the response to intensive treatments should be judged within 6 to 12 months [135].

Peripheral, staged embolization of liver VMs seems the most effective and repeatable transarterial treatment [149]. HOCF has been the main indication in these treated patients. However, a significant morbidity and 10% of fatal complications, together with its palliative role suggest caution in its use, which can be proposed only in severely symptomatic liver VMs not amenable to transplant [142,143].

OLT represents the only definitive curative option for hepatic VMs in HHT, and is indicated for ischemic biliary necrosis, intractable HOCF and complicated PH [142,143]. Post-operative mortality of OLT in HHT is 7–10%, with a long-term survival ranging between 82 and 92% [144,145].

Right heart catheterisation should always be performed in patients with HHT being evaluated for OLT, to exclude severe pulmonary hypertension: OLT may be allowed in HHT patients with pulmonary vascular resistance  $<240$  dynes  $\text{sec cm}^{-5}$  [142].

Bevacizumab, an angiogenesis inhibitor, has shown the ability to reduce the cardiac index in 24 patients with severe liver VMs and high cardiac output, with complete and partial response in 12% and 70%, respectively [150]. However, critical issues need to be carefully weighed regarding the use of bevacizumab; namely its unpredictable efficacy and non-negligible toxicity, revascularization following drug withdrawal, and problems with respects to angiogenesis-dependent phenomena such as wound and anastomoses healing, which could be critical in patients requiring emergency OLT.

The subset of patients with severe grade 4 liver VMs, at high risk of poor outcome, could be the target for prophylactic treatments. In the case of cardiac overload, angiotensin-converting enzyme inhibitors or carvedilol could be used to prevent cardiac remodeling, while for PH, beta blockers could be proposed to prevent gastrointestinal bleeding either from varices or from gastrointestinal telangiectasias [135].

## Recommendations:

1. Consider HHT in subjects presenting with diffuse liver VMs, which are either complicated or not **(A2)**
2. Investigation for liver VMs are to be completed:
  - In HHT patients with symptoms/signs suggestive of complicated liver VMs (High-Output Cardiac Failure, ascites, gastrointestinal bleeding, cholangitis, encephalopathy and mesenteric angina) **(A1)**
  - In all subjects at risk for HHT, as liver VMs diagnosis and staging offer the advantages of a proper patient management and follow-up **(A2)**
3. Doppler ultrasound is the ideal first line imaging for the diagnosis and staging of liver VMs. Wherever expertise of Doppler ultrasound is lacking, multiphase CT is a suitable alternative to investigate symptomatic liver VMs **(A1)**
4. Propose echocardiographic evaluation to patients with liver VMs, particularly if severe (grade 3-4), at baseline and during follow-up, to monitor haemodynamic impact of liver VMs **(B2)**
5. Liver biopsy:
  - a. Is not necessary in the diagnosis of hepatic VMs related to HHT **(A1)**
  - b. If needed for other reasons, in a patient with known or suspected HHT, consider the risk of increased bleeding with percutaneous transcapsular route. **(A1)**
6. Discuss Focal Nodular Hyperplasia first in a HHT patient with liver mass(es), and use non-invasive, contrast enhanced imaging for diagnostic confirmation **(B1)**
7. Take advice from a medical team with expertise in HHT before making any decision regarding treatment of liver VMs, and notably OLT **(A1)**
8. Only in HHT patients who failed to respond to intensive medical therapy consider invasive therapies for liver involvement. Obtain assessment and treatment by a cardiologist for HOCF prior to considering an invasive therapy **(B1)**
9. Regard transarterial embolization of liver VMs as a palliative, temporizing and risky procedure, to be discussed in patients with HOCF or mesenteric angina who are not candidates for OLT. Consider cholangiopathy as a contraindication to transarterial embolization **(B2)**
10. Regard OLT as the only curative treatment for liver VMs, if intractable HOCF or PH, and urgently, for ischemic bile duct necrosis **(B1)**

**Sinusoidal obstruction syndrome – veno-occlusive disease of the liver**

Sinusoidal obstruction syndrome (SOS, previously named veno-occlusive disease or VOD), is characterized morphologically by a loss of sinusoidal wall integrity. Sinusoidal endothelial cells at first become injured and detach from the wall (endothelium denudation), followed by cell embolization and sloughing towards central zones of hepatic lobules, and a subsequent sinusoidal congestive obstruction by outflow block. According to the level of obstruction, various degrees of centrilobular hepatocellular necrosis may occur. SOS may also be associated with one or more other lesions such as centrilobular perisinusoidal and endovenular fibrosis, peliosis and nodular regenerative hyperplasia (NRH).

SOS is a well-established hepatic complication of myeloablative regimens used in the setting of haematopoietic stem cell transplantation (HSCT). A large number of drugs and toxins have also been associated with SOS including several chemotherapeutic agents used in adjuvant or neo-adjuvant treatments of solid cancer, or immunosuppressors applied in the context of organ transplantation or inflammatory bowel diseases. Total body or hepatic irradiation and platelet transfusion containing ABO-incompatible plasma represents other reported associated conditions (Table 5). SOS can engender significant morbidity and mortality in all these settings [54,151]. Pathogenesis of SOS is not yet conclusively established. The establishment of a rat model based on monocrotaline (pyrrolizidine alkaloid) gavage was a milestone and lead to a better understanding of SOS pathogenesis, both at the morphological and biochemical levels [152].

**Table 5. Major causes of sinusoidal obstruction syndrome.**

• Actinomycin D
• Azathioprine
• Busulfan
• Carmustine
• Cytosine arabinoside
• Cyclophosphamide
• Dacarbazine
• Gemtuzumab-ozogamicin
• Melphalan
• Mercaptopurine
• Mitomycin
• Oxaliplatin
• Pyrrolizidine alkaloids
• Urethane
• Terbinafine
• Traditional herbal remedies
• 6-mercaptopurine
• 6-thioguanine
• Post-bone marrow transplant
• Total-body irradiation
• Hepatic irradiation (high doses)
• Platelet transfusion containing ABO-incompatible plasma

*Incidence*

Many studies have been based on clinical criteria whose specificity and sensitivity may vary greatly according to the context. SOS incidence differs considerably according to patient risk factors, type of drug regimen, number of cycles of chemotherapy, diversity in clinical or in histological diagnostic criteria.

SOS incidence has declined in HSCT from 50% [153] to currently about 14% [154], and in solid transplantation as well. Decreased incidence has been attributed to the development of prophylactic therapy, avoidance of cyclophosphamide containing regimens, and lower doses of total body irradiation in HSCT, and lesser use of azathioprine in solid organ transplantation. However, other drugs and settings may be responsible for SOS (Table 5). The incidence in these cases are less well-established.

*Clinical manifestations and outcome*

The typical signs and symptoms are; weight gain due to fluid retention with or without ascites, tender hepatomegaly and jaundice [155]. Clinical presentation may however range from the absence of symptoms to features of PH and severe multiorgan dysfunction that may lead to death.

In the context of HSCT, clinical onset usually occurs in the first 20 days in SOS due to cyclophosphamide, and later with other regimens. According to clinical course severity, SOS may be subdivided into three forms: mild SOS (self-limiting disease not requiring treatment); moderate SOS (resolving disease nevertheless requiring treatment notably for fluid retention); and severe SOS (disease not resolving after day 100 despite treatment, that may lead to death). Major parameters of poor outcome (mostly validated for cyclophosphamide-related SOS), are high serum bilirubin and level of weight gain. Other parameters are aminotransferase rise, high hepatic venous pressure gradient, renal function and multiorgan failure. Death is most commonly caused by renal, cardiopulmonary or liver failure. Mortality rate at 100 days is 9% in mild cases to near 100% in patients with clinically severe SOS.

In the context of oxaliplatin chemotherapy regimen (used for downstaging colorectal liver metastasis (CRLM) before surgical hepatic resection), SOS is associated with a decreased liver metastases imaging detections [155], an increased operative bleeding [156], and post-operative liver dysfunction or a delay in liver regeneration [157,158].

The time frame for regression of SOS and associated lesions (centrilobular fibrosis and NRH) remains unknown. SOS and NRH persisted histologically in the setting of a two stage hepatectomies for CRLM (where liver surgery of the same patient is performed with an interval of 4 to 7 weeks with no chemotherapy applied during this interval) [159], as in several cases that underwent iterative hepatic surgery for recurrence with a gap of several months. PH, evaluated by spleen size, improved only between 1 to 3 years after completing oxaliplatin treatment [160]. It is noteworthy that in several cases persistence or progression of a histological lesion and signs of PH have been observed.

Despite an apparently indolent initial course, delayed complications of SOS may occur. In toxic oil syndrome, PH appeared 2.5 years after consuming the oil, as with azathioprine and 6-thioguanine, sinusoidal lesions persist at biopsy and become symptomatic over time.

## Clinical Practice Guidelines

### Diagnosis

Currently, the absence of specific clinical signs or serological diagnostic tool makes recognition of SOS challenging. Diagnosis is essentially based on a high index of clinical suspicion, after exclusion of other potential mimicking causes (Table 6), resulting in various levels of diagnostic accuracy (up to 20% of patients cannot be clinically diagnosed with certainty) and potential risks of error. Clinical features for diagnosis have been formalized in the Seattle or Baltimore criteria; their sensitivity and specificity have not been well-defined and their use in the different settings of SOS aetiology have not been evaluated. According to regimens, delay in clinical onset of SOS after initiation of therapy varies and some features may be lacking.

Increase in serum bilirubin is a sensitive but not specific marker of SOS. Other markers have been proposed, including serum procollagen, plasminogen activator inhibitor-1, platelet count less than 167,000/ $\mu$ l, high APRI or FIB-4 scores but not independently validated yet [161].

There are no definitive ultrasound features for early SOS diagnosis. Doppler ultrasound may show signs of PH, and liver and spleen enlargement [162–164]. Reversal of flow in the portal vein and monophasic flow in the hepatic vein have been used to diagnose SOS but lacks sensitivity [165]. CT scan is not recommended because of the toxicity of contrast agents. MR imaging may show patients hepatic veins and patchy signal enhancement compatible with the diagnosis of histologically severe SOS [166–168].

Transjugular liver biopsy combined with measurement of the wedged hepatic venous pressure gradient is of major help in confirming the diagnosis [169,170,170]. Regardless of its cause, SOS has similar pathological features [171]. According to the level of obstruction, various degrees of centrilobular hepatocellular necrosis may occur. SOS may also be associated with centrilobular perisinusoidal and endovenular fibrosis, peliosis and NRH [172]. Except peliosis, all these lesions are morphologically distinct from sinusoidal changes, although they appear to be related to its severity [169,172] or represent late lesions. Occlusion of the centrilobular veins occurs only in 50% of patients with mild to moderate SOS and up to 75% of patients with severe SOS after HSCT [169], and in around 50% of patient with oxaliplatin-related SOS [156,171,172]. Therefore, the alternate terms of SOS was proposed in replacement of VOD. Percutaneous biopsy is often contraindicated by thrombocytopenia, coagulopathy or ascites.

Despite patchy distribution of SOS lesions, liver biopsy findings have been reported to influence treatment decisions in around 90% of patients [173,174]. Combining biopsy with haemodynamic evaluation helps in the overall sensitivity. Hepatic venous pressure gradient >10 mmHg has a sensitivity of 52% and a specificity of 91% with a positive predictive value greater than 85% for the diagnosis of SOS in the context of HSCT. Despite advanced imaging modalities, histology currently remains the optimal means for the diagnosis of fibrosis and NRH. From a pathologist's perspective, the diagnosis of NRH can be challenging and reticulin staining is needed.

### Prophylaxis and treatment

Recognition of risk factors is helpful for the prevention of SOS [161,175]. Risk factors include pre-existing liver disease, previous episode of SOS and type of regimen; and, in the context of solid cancer treatment (in particular colorectal liver metastasis), abnormal preoperative gamma-glutamyl transpeptidase, age, female gender, indocyanin green retention rate at 15 minutes,

number of cycles of chemotherapy and a short interval between the end of chemotherapy and surgical liver resection. Polymorphisms of the glutathione S-transferase gene (coding for enzymes catabolizing chemotherapeutic drugs) have been associated with a risk of SOS [176].

Reduction of the intensity of myeloablative regimens or choice of regimens that carry lower risk of SOS has to be counterbalanced with a possible lower anti-tumoral efficacy or appearance of other complications.

Defibrotide (single-stranded oligodeoxyribonucleotides mixture extracted from porcine intestinal mucosal DNA with multiple antithrombotic, fibrinolytic and angiogenic properties) has demonstrated a benefit for SOS prophylaxis in a randomized study in pediatric HSCT [177]. A meta-analysis of the effects of heparin showed no positive effect [178].

Indications for treatment of SOS depend on its clinical severity. There are still no solid data to give firm recommendations [179]. Treatment of SOS relies mostly on supportive care with therapy of fluid retention, sepsis and organ failure. TIPS, surgical shunting and liver transplantation have been used essentially in individual cases as a rescue therapy; more data and prospective studies are needed to confidently indicate the value of this treatment approach in SOS. Liver transplantation is however limited by the underlying malignancy which may itself be a contraindication and should be proposed only to patients with favourable oncologic prognosis or non-oncologic aetiology.

### Recommendations:

1. Consider a diagnosis of SOS whenever liver disease occurs in patients with haematopoietic stem cell transplantation, chemotherapy for cancers, or immunosuppression in solid organ transplantation or inflammatory bowel (B1)
2. Consider SOS in patients with weight gain, associated with or without ascites, tender hepatomegaly and jaundice. Exclude other common causes of these symptoms including sepsis, other types of drug toxicity and graft versus host disease (C1)
3. In patients who do not meet clinical criteria of SOS or when other diagnoses have to be excluded, use transjugular liver biopsy, and haemodynamic evaluation (C1)
4. Routinely control risk factors for SOS (B1)
5. Use defibrotide for the prevention of SOS undergoing haematopoietic stem cell transplantation (B2). Other means for prophylaxis need further investigation
6. Use supportive measures for the treatment of complications of established SOS (B1)

### Cirrhosis as a prothrombotic condition. Portal vein obstruction

#### Introduction

Venous thromboembolism (VTE), once considered unlikely in cirrhosis, has recently been documented to occur [180,181] not only

**Table 6. Major differential diagnosis of sinusoidal obstruction syndrome.**

• Acute liver graft versus host disease (GVH)
• Liver infections (virus, fungi)
• Sepsis associated cholestasis
• Other drug-induced liver diseases
• Cardiac diseases
• Other causes of ascites
• Parenteral nutrition
• Haemolysis
• Renal failure

in the portal system, but also in the lower limbs and in the lung. Recently, a procoagulant imbalance was demonstrated in cirrhotic patients probably due to increased levels of factor VIII (procoagulant driver) combined with decreased levels of protein C (anticoagulant driver) [182]. These features are common in patients with cirrhosis and may explain the increased risk of VTE. This new concept makes the treatment with anticoagulants such as heparins or VKA, once regarded as contraindicated, possible in patients with cirrhosis who present with thrombosis.

*Incidence and prevalence of PVT in cirrhosis*

PVT is the most common of thrombotic events occurring in cirrhotic patients, with a reported prevalence ranging from 2.1% to 23.3% in published series of transplant candidates without HCC [183]. Incidence at 1 year has been described to be 7.4% and 11% in two cohort studies, respectively [184,185]. In the general population, the presence of cirrhosis is associated with a relative risk of 7.3 of developing non-neoplastic PVT [186].

*Manifestations*

PVT in cirrhotic patients is often asymptomatic and detected at follow-up ultrasound evaluation. In other instances, PVT is diagnosed in coincidence with a liver decompensation. PVT has been shown to be independently associated with a higher risk of variceal bleeding, failure of endoscopic control of bleeding and rebleeding, leading to an increased 6 week mortality (36% in PVT vs. 16% in non-PVT patients) [187–189]. In those patients with extension of the thrombus into the superior mesenteric vein the risk of intestinal infarction and associated mortality is higher [190]. Englesbe *et al.* showed an increased mortality in cirrhotic patients with occlusive PVT listed for liver transplantation, independently from transplant (HR 1.99) [191]. Moreover, among all the published studies, the presence of PVT was associated with a significant increase in 30-day and 1-year mortality post-LT when compared to patients without PVT [183]. However, only complete PVT accounted for this increased mortality, also confirmed in a study from the registry data [191].

*Risk factors*

The occurrence of pathological thrombosis is determined by an alteration in the physiological equilibrium that regulates

coagulation and anticoagulation dynamics as one of the components of Virchow’s triad. In cirrhotic patients the pathogenesis of PVT is likely to be multifactorial. Reduced portal flow velocity was associated with higher risk of developing PVT in one study [185]. The possible role of thrombophilic genetic defects has been investigated in several cohorts and *G20210A* prothrombin gene variant has been the most common abnormality associated with PVT [192,193]. Moreover the occurrence of PVT has been associated with more advanced liver disease (Child-Pugh C), presence of portal hypertensive complications and previous endoscopic sclerotherapy of oesophageal varices [183].

*Diagnosis*

The diagnosis of PVT is often made during routine ultrasound in asymptomatic patients, or once a new event of hepatic decompensation occurs. Doppler ultrasound is the first line method used, with sensitivity of about 90% for complete PVT which decreases to about 50% for partial PVT [183]. CT scan or MR imaging can better define the extension of PVT into the other splanchnic vessels. The presence of neoplastic infiltration of the portal vein has been shown to be associated in patients with underlying HCC, high serum alpha-fetoprotein levels, enlarged portal vein diameter, enhancement of the thrombus in the arterial phase of contrast injection at CT scan or contrast ultrasound [194], or an arterial-like flow observed on Doppler ultrasound [195].

*Treatment*

A recent randomized controlled trial has shown that enoxaparin 4000 IU daily for 1 year is able to completely prevent the occurrence of PVT, without increasing bleeding complications [196].

Spontaneous complete recanalisation of the portal vein may occur, mainly when thrombosis is partial [197,198]. Progression of thrombosis has also been reported in 48% up to 70% of patients at 2 years follow-up [197,199]. Data on the efficacy of medical anticoagulation to treat PVT come from five cohort studies [184,199–202] which included 163 anticoagulated patients, most with partial PVT, with different regimens (LMWH or VKA). Repermeation rate ranged from 55% to 75% with a mean interval time of about 6 months. Time interval between diagnosis of PVT and start of anticoagulation treatment less than 6 months, seems to be the most important factor able to predict the chance of response to anticoagulation [199]. When anticoagulation has been stopped soon after repermeation of the PV recurrence of thrombosis has been reported in up to 38% of cases after a few months [201]. This observation suggests that the prolongation of anticoagulation treatment after repermeation of the PV may prevent rethrombosis. Overall, bleeding complications were seen in 9/163 (5%) patients and correlated with PH in three cases. A multicentre study showed a correlation between platelet count less than  $50 \times 10^9/L$  and risk of bleeding [201].

Either beta blockers or band ligation can be used to prevent variceal bleeding before anticoagulation. TIPS has been shown to be feasible in the presence of PVT, even in some cases with cavernous transformation [117,199,203,204]. However, in most cases the indication for TIPS was not PVT per se, but

## Clinical Practice Guidelines

complications of PH. Therefore, the applicability of TIPS to treat PVT is unknown. The thrombotic occlusion of the intrahepatic portal vein branches compels the use of transcutaneous approach with associated increased risk of complications [205,206]. While waiting for the results of randomized controlled trials, each institution/liver unit should define its own algorithm of treatment of PVT in cirrhosis, based on its experience, pattern of referral, etc. Candidacy to liver transplantation, degree and extent of occlusion, underlying conditions, past history and presence of PH complications among others need to be taken into account when designing such an algorithm.

### Recommendations:

1. Evaluate portal vein patency in all patients with cirrhosis listed or potential candidates for liver transplantation (**B2**)
2. Always evaluate the extension of PVT with CT scan or MR imaging (**A1**)
3. In patients with underlying HCC, rule out neoplastic PVT by contrast enhanced ultrasound/CT scan/MR imaging or biopsy of the thrombus (**A1**)
4. Consider screening for underlying genetic thrombophilic conditions in patients with PVT and cirrhosis (**B2**)
5. Anticoagulation must be started always after implementing an adequate prophylaxis for gastrointestinal bleeding (**A1**)
6. Consider anticoagulation at therapeutic dose for at least 6 months (**B1**)
7. In patients with superior mesenteric vein thrombosis, with a past history suggestive of intestinal ischemia or liver transplant candidates, consider lifelong anticoagulation (**C2**)
8. Once PVT has been repermeated, consider prolonging anticoagulation for some months and until transplant in liver transplant candidates (**B2**)
9. In liver transplant candidates, who have progressive PVT not responding to anticoagulation, consider referring the patients for TIPS (**B2**)

### Management of anticoagulation in patients with liver disease

#### Heparins

##### Background

The American College of Chest Physicians Evidence-Based Clinical Practice Guidelines [207] for acute VTE [including deep vein thrombosis, pulmonary embolism and SVT (i.e., mesenteric, portal and hepatic vein thromboses)] in non-liver disease patients, recommend initial parenteral anticoagulation. LMWH or fondaparinux is suggested over intravenous or subcutaneous unfractionated heparin (UFH). All the above anticoagulants require

binding to endogenous antithrombin in order to exert their anticoagulant action. Unfractionated heparin upon binding to antithrombin neutralizes both FXa and thrombin, whereas LMWH and fondaparinux neutralizes predominantly FXa [208]. Unfractionated heparin is mainly given as IV injection and requires laboratory monitoring by the activated partial thromboplastin time (APTT). The UFH therapeutic interval should be 1.5–2.5 times over the normal APTT. However, this therapeutic interval is uncertain because it has not been confirmed by controlled trials and is also dependent on the reagent/instrument used for testing (not yet standardized). The 1.5–2.5 APTT therapeutic intervals corresponds to approximately 0.3–0.7 U/ml anti-Xa. However, like the APTT also the standardization of anti-Xa assays is far reaching, so that also the definition of the anti-Xa therapeutic interval is problematic. Because of the above limitations and other complications associated with its uses (i.e., the risk of HIT, osteoporosis, etc.), unfractionated heparin has been gradually replaced by LMWH, notwithstanding that it can be rapidly reversed by protamine-sulphate.

LMWH is given subcutaneously once daily or twice daily in a fixed dose for thromboprophylaxis and in a weight-adjusted dose for therapeutic purposes. Laboratory monitoring is not generally required, but it has been suggested in obesity, renal insufficiency or pregnancy [208]. Fondaparinux is given subcutaneously once daily in a fixed dose, without laboratory monitoring.

#### Liver disease patients

The major concern on the use of heparins in cirrhosis is the reduction of antithrombin that is a typical feature of patients with advanced disease. The crucial question is whether fixed- or weight-adjusted LMWH doses that are effective/safe in non-liver disease patients are equally effective/safe in cirrhotic patients. The direct consequence of this question is whether or not LMWH in cirrhosis requires laboratory monitoring to adjust the dosage. Experience is still insufficient and is limited to a few non-randomized studies (reviewed in [209]), and to *in vitro* studies using the plasmas from cirrhotic patients treated with LMWH [210–212]. Briefly, the non-randomized studies showed that LMWH when used at fixed prophylactic dose (4000 IU/day SC) and without laboratory monitoring was effective and safe in patients with PVT [209]. The *in vitro* studies gave conflicting results that can be summarized as follows. The anti-Xa assay is not the assay of choice to measure the LMWH anticoagulant effect [210,211]. Conversely, thrombin generation assays seem more suitable for this task, but are not available in every haemostasis laboratory and need to be evaluated [212]. Finally, plasma from cirrhotic patients seem more responsive to the anticoagulation mediated by LMWH, despite the fact that they have low antithrombin levels [212]. The only randomized trial so far carried out showed that LMWH when used at a fixed prophylactic dose and without laboratory monitoring was effective and safe in preventing PVT in cirrhotic patients [196].

#### Vitamin K antagonists

##### Background

VKA are the drugs of choice for prevention of stroke and systemic embolism in atrial fibrillation, patients with mechanical

prosthetic heart-valves, and treatment/prevention of VTE after the first event in non-liver disease patients. VKA are coumarin-like drugs that interfere with the carboxylation of vitamin K-dependent coagulation factors, thus limiting their activity. Owing to the relatively narrow therapeutic window, VKA need strict laboratory monitoring to adjust the dose and maintain the patients within the therapeutic interval [213]. The test of choice is the prothrombin time (PT) with results expressed as INR. Briefly, the INR is the ratio (patient-to-normal) of PT raised to a power equal to the international sensitivity index (ISI) according to the following equation:

$$\text{INR} = (\text{PT}_{\text{patient}}/\text{PT}_{\text{normal}})^{\text{ISI}}$$

The ISI, being characteristic for each thromboplastin/coagulometer, represents the slope of the relationship of the PT determined with the standard and the working thromboplastin/coagulometer for plasmas from healthy subjects and patients stabilized on VKA [214]. By definition the INR scale is valid only for patients on VKA and no other superimposed coagulation defect [214], and any other use warrants validation and possible modification. VKA dose-adjustment is aimed at maintaining patients within the therapeutic interval corresponding to 2.0–3.0 INR (target 2.5).

#### Liver disease patients

The main concern on the use of VKA in cirrhosis is that the baseline-PT is often prolonged. This implies that the attainment of the therapeutic interval requires probably smaller VKA doses, thus cirrhotic patients could be under-dosed. No studies whatsoever have yet to address this issue and cirrhotic patients are currently treated with VKA doses aimed at 2.0–3.0 INR. The second concern on VKA in cirrhosis is the use of the INR as the scale to express PT results. As demonstrated by independent groups (reviewed in [215]) the regular INR (here called INR-vka) is not valid for cirrhotic patients and hence cannot minimize the variability of the INR obtained in laboratories using different thromboplastins. As a consequence the INR-vka obtained in any given laboratory may or may not be representative of the real anticoagulation achieved with the specific dose. An alternative to this scale would be the modified-INR, valid for cirrhosis (called INR-liver) that has been developed [215], but not yet investigated for its value in assessing survival in patients with cirrhosis nor for monitoring patients with cirrhosis on VKA.

#### Direct oral anticoagulants (DOAC)

These are drugs that (unlike VKA) target directly specific activated factors such as thrombin (dabigatran) or FXa (rivaroxaban and apixaban) without intermediation by antithrombin or carboxylation. DOAC have been licensed for atrial fibrillation and treatment/prophylaxis of VTE (reviewed in [216]). Cirrhotic patients have been deliberately excluded from phase III trials and therefore (although they might have some theoretical advantages over heparins or VKAs) [182] no information is currently available in this setting. The main advantage of DOAC is that they do not require dose-adjustment by laboratory tests, thus the issue on the validity of the INR in this setting could be eliminated. Recently, it has been reported that treatment with rivaroxaban can be associated with severe symptomatic liver injury [217]. Caution should be exerted until this issue is addressed in clinical trials.

#### Recommendations:

**Unfractionated heparin** should be used with laboratory monitoring with the APTT as the test for dose-adjustment and a therapeutic interval aimed at 1.5–2.5 prolongation over the normal value (C2), keeping in mind that the above therapeutic interval may vary between centres depending on the reagent being used for testing. An additional problem is that the baseline APTT in cirrhosis is often prolonged beyond normal and therefore unfractionated heparin will probably be under-dosed. For the above reasons unfractionated heparin is probably not indicated in cirrhosis.

**Low molecular weight heparin** should be used at fixed or weight-adjusted dose for prophylaxis or treatment without laboratory monitoring. From the limited experience thus far the anti-Xa assay in cirrhosis is not representative of the real anticoagulation. Patients who are obese, those with renal insufficiency or during pregnancy should be strictly monitored by regular clinical visits and should be advised to report immediately any sign that may be suggestive of adverse event (C2).

**Vitamin K antagonists** should be used by regular laboratory monitoring with an INR aimed at the therapeutic interval 2.0–3.0, the limitation, inherent in the use of this scale in cirrhosis should be kept in mind: the INR value might not be representative of the real anticoagulation and the results may vary between centres (C2).

**Warning.** Before deciding anticoagulation, consider carefully the risk/benefit ratio for individual patients. Risk factors for bleeding are oesophageal varices if not treated prior to anticoagulation and severe thrombocytopenia (C2). Type and duration of anticoagulation are discussed in the specific sections of these guidelines.

#### Future investigations

Randomized trials are urgently needed to assess the efficacy/safety especially of LMWH, VKA and DOAC in cirrhosis. Alternative laboratory monitoring should be developed and validated in cirrhotic patients treated with LMWH or VKA.

#### Conflict of interest

All the authors who have taken part in this CPG declared that they do not have anything to disclose regarding funding or conflict of interest with respect to this manuscript.

#### Acknowledgements

We would like to thank the reviewers of these guidelines for their time and critical reviewing; Yogesh Chawla and Paolo Angeli.

#### References

- [1] Janssen HL, Garcia-Pagan JC, Elias E, Mentha G, Hadengue A, Valla DC. Budd-Chiari syndrome: a review by an expert panel. *J Hepatol* 2003;38:364–371.
- [2] Darwish MS, Plessier A, Hernandez-Guerra M, Fabris F, Eapen CE, Bahr MJ, et al. Etiology, management, and outcome of the Budd-Chiari syndrome. *Ann Intern Med* 2009;151:167–175.

# Clinical Practice Guidelines

- [3] Plessier A, Darwish MS, Hernandez-Guerra M, Consigny Y, Fabris F, Trebicka J, et al. Acute portal vein thrombosis unrelated to cirrhosis: a prospective multicenter follow-up study. *Hepatology* 2010;51:210–218.
- [4] Denninger MH, Chait Y, Casadevall N, Hillaire S, Guillin MC, Bezeaud A, et al. Cause of portal or hepatic venous thrombosis in adults: the role of multiple concurrent factors. *Hepatology* 2000;31:587–591.
- [5] Valla D, Casadevall N, Huisse MG, Tulliez M, Grange JD, Muller O, et al. Etiology of portal vein thrombosis in adults. A prospective evaluation of primary myeloproliferative disorders. *Gastroenterology* 1988;94:1063–1069.
- [6] Mohanty D, Shetty S, Ghosh K, Pawar A, Abraham P. Hereditary thrombophilia as a cause of Budd-Chiari syndrome: a study from Western India. *Hepatology* 2001;34:666–670.
- [7] Uskudar O, Akdogan M, Sasmaz N, Yilmaz S, Tola M, Sahin B. Etiology and portal vein thrombosis in Budd-Chiari syndrome. *World J Gastroenterol* 2008;14:2858–2862.
- [8] El-Karakasy H, El-Raziky M. Splanchnic vein thrombosis in the mediterranean area in children. *Mediterr J Hematol Infect Dis* 2011;3:e2011027.
- [9] Middeldorp S, van Hylckama Vlieg A. Does thrombophilia testing help in the clinical management of patients? *Br J Haematol* 2008;143:321–335.
- [10] Janssen HL, Meinardi JR, Vlegaar FP, van Uum SH, Haagsma EB, Der Meer FJ, et al. Factor V Leiden mutation, prothrombin gene mutation, and deficiencies in coagulation inhibitors associated with Budd-Chiari syndrome and portal vein thrombosis: results of a case-control study. *Blood* 2000;96:2364–2368.
- [11] Smalberg JH, Darwish MS, Braakman E, Valk PJ, Janssen HL, Leebeek FW. Myeloproliferative disease in the pathogenesis and survival of Budd-Chiari syndrome. *Haematologica* 2006;91:1712–1713.
- [12] Primignani M, Martinelli I, Bucciarelli P, Battaglioli T, Reati R, Fabris F, et al. Risk factors for thrombophilia in extrahepatic portal vein obstruction. *Hepatology* 2005;41:603–608.
- [13] Leebeek FW, Lameris JS, van Buuren HR, Gomez E, Madretsma S, Sonneveld P. Budd-Chiari syndrome, portal vein and mesenteric vein thrombosis in a patient homozygous for factor V Leiden mutation treated by TIPS and thrombolysis. *Br J Haematol* 1998;102:929–931.
- [14] Smalberg JH, Kruijff MJ, Janssen HL, Rijken DC, Leebeek FW, de Maat MP. Hypercoagulability and hypofibrinolysis and risk of deep vein thrombosis and splanchnic vein thrombosis: similarities and differences. *Arterioscler Thromb Vasc Biol* 2011;31:485–493.
- [15] Dentali F, Galli M, Gianni M, Ageno W. Inherited thrombophilic abnormalities and risk of portal vein thrombosis: a meta-analysis. *Thromb Haemost* 2008;99:675–682.
- [16] Miyakis S, Lockshin MD, Atsumi T, Branch DW, Brey RL, Cervera R, et al. International consensus statement on an update of the classification criteria for definite antiphospholipid syndrome (APS). *J Thromb Haemost* 2006;4:295–306.
- [17] Martinelli I, Primignani M, Aghemo A, Reati R, Bucciarelli P, Fabris F, et al. High levels of factor VIII and risk of extra-hepatic portal vein obstruction. *J Hepatol* 2009;50:916–922.
- [18] Raffa S, Reverter JC, Seijo S, Tassies D, Abrales JG, Bosch J, et al. Hypercoagulability in patients with chronic noncirrhotic portal vein thrombosis. *Clin Gastroenterol Hepatol* 2012;10:72–78.
- [19] Marchetti M, Castoldi E, Spronk HM, van Oerle R, Balducci D, Barbui T, et al. Thrombin generation and activated protein C resistance in patients with essential thrombocythemia and polycythemia vera. *Blood* 2008;112:4061–4068.
- [20] Tripodi A, Primignani M, Lemma L, Chantarangkul V, Mannucci PM. Evidence that low protein C contributes to the procoagulant imbalance in cirrhosis. *J Hepatol* 2013;59(2):265–270.
- [21] Kiladjian JJ, Cervantes F, Leebeek FW, Marzac C, Cassinat B, Chevret S, et al. The impact of JAK2 and MPL mutations on diagnosis and prognosis of splanchnic vein thrombosis: a report on 241 cases. *Blood* 2008;111:4922–4929.
- [22] Colaizzo D, Amitrano L, Tiscia GL, Grandone E, Guardascione MA, Margaglione M. A new JAK2 gene mutation in patients with polycythemia vera and splanchnic vein thrombosis. *Blood* 2007;110:2768–2769.
- [23] Chait Y, Condat B, Cazals-Hatem D, Rufat P, Atmani S, Chaoui D, et al. Relevance of the criteria commonly used to diagnose myeloproliferative disorder in patients with splanchnic vein thrombosis. *Br J Haematol* 2005;129:553–560.
- [24] Smalberg JH, Arends LR, Valla DC, Kiladjian JJ, Janssen HL, Leebeek FW. Myeloproliferative neoplasms in Budd-Chiari syndrome and portal vein thrombosis: a meta-analysis. *Blood* 2012;120:4921–4928.
- [25] Janssen HL, Leebeek FW. JAK2 mutation: The best diagnostic tool for myeloproliferative disease in splanchnic vein thrombosis? *Hepatology* 2006;44:1391–1393.
- [26] Campo E, Swerdlow SH, Harris NL, Pileri S, Stein H, Jaffe ES. The 2008 WHO classification of lymphoid neoplasms and beyond: evolving concepts and practical applications. *Blood* 2011;117:5019–5032.
- [27] Klampfl T, Gisslinger H, Harutyunyan AS, Nivarthi H, Rumi E, Milosevic JD, et al. Somatic mutations of calreticulin in myeloproliferative neoplasms. *N Engl J Med* 2013;369:2379–2390.
- [28] Nangalia J, Massie CE, Baxter EJ, Nice FL, Gundem G, Wedge DC, et al. Somatic CALR mutations in myeloproliferative neoplasms with nonmutated JAK2. *N Engl J Med* 2013;369:2391–2405.
- [29] Turon F, Cervantes F, Colomer D, Baiges A, Hernandez-Gea V, Garcia-Pagan JC. Role of calreticulin mutations in the aetiological diagnosis of splanchnic vein thrombosis. *J Hepatol* 2015;62:72–74.
- [30] Plompen EP, Valk PJ, Chu I, Darwish MS, Plessier A, Turon F, et al. Somatic calreticulin mutations in patients with Budd-Chiari syndrome and portal vein thrombosis. *Haematologica* 2015;100(6):e226–e228.
- [31] Landolfi R, Di GL, Falanga A. Thrombosis in myeloproliferative disorders: pathogenetic facts and speculation. *Leukemia* 2008;22:2020–2028.
- [32] Ziakas PD, Poulou LS, Rokas GI, Bartzoudis D, Voulgarelis M. Thrombosis in paroxysmal nocturnal hemoglobinuria: sites, risks, outcome. An overview. *J Thromb Haemost* 2007;5:642–645.
- [33] Hoekstra J, Leebeek FW, Plessier A, Raffa S, Murad SD, Heller J, et al. Paroxysmal nocturnal hemoglobinuria in Budd-Chiari syndrome: findings from a cohort study. *J Hepatol* 2009;54(5):908–914.
- [34] Brodsky RA. Narrative review: paroxysmal nocturnal hemoglobinuria: the physiology of complement-related hemolytic anemia. *Ann Intern Med* 2008;148:587–595.
- [35] van Bijnen ST, van Rijn RS, Koljenovic S, te Boekhorst P, de Witte T, Muus P. Possible high risk of thrombotic events in patients with paroxysmal nocturnal hemoglobinuria after discontinuation of eculizumab. *Br J Haematol* 2012;157:762–763.
- [36] Bayraktar Y, Balkanci F, Bayraktar M, Calguneri M. Budd-Chiari syndrome: a common complication of Behcet's disease. *Am J Gastroenterol* 1997;92:858–862.
- [37] Justo D, Finn T, Atzmony L, Guy N, Steinvil A. Thrombosis associated with acute cytomegalovirus infection: a meta-analysis. *Eur J Intern Med* 2011;22:195–199.
- [38] Kochhar R, Masoodi I, Dutta U, Singhal M, Miglani A, Singh P, et al. Celiac disease and Budd Chiari syndrome: report of a case with review of literature. *Eur J Gastroenterol Hepatol* 2009;21:1092–1094.
- [39] Valla D, Le MG, Poynard T, Zucman N, Rueff B, Benhamou JP. Risk of hepatic vein thrombosis in relation to recent use of oral contraceptives. A case-control study. *Gastroenterology* 1986;90:807–811.
- [40] Amitrano L, Guardascione MA, Scaglione M, Pezzullo L, Sangiuliano N, Armellino MF, et al. Prognostic factors in noncirrhotic patients with splanchnic vein thromboses. *Am J Gastroenterol* 2007;102:2464–2470.
- [41] Spaander MC, Hoekstra J, Hansen BE, van Buuren HR, Leebeek FW, Janssen HL. Anticoagulant therapy in patients with non-cirrhotic portal vein thrombosis: effect on new thrombotic events and gastrointestinal bleeding. *J Thromb Haemost* 2013;11:452–459.
- [42] Condat B, Pessione F, Hillaire S, Denninger MH, Guillin MC, Poliquin M, et al. Current outcome of portal vein thrombosis in adults: risk and benefit of anticoagulant therapy. *Gastroenterology* 2001;120:490–497.
- [43] Plessier A, Rautou PE, Valla DC. Management of hepatic vascular diseases. *J Hepatol* 2012;56:S25–S38.
- [44] Tait C, Baglin T, Watson H, Laffan M, Makris M, Perry D, et al. Guidelines on the investigation and management of venous thrombosis at unusual sites. *Br J Haematol* 2012;159:28–38.
- [45] Baglin T, Gray E, Greaves M, Hunt BJ, Keeling D, Machin S, et al. Clinical guidelines for testing for heritable thrombophilia. *Br J Haematol* 2010;149:209–220.
- [46] Hoekstra J, Bresser EL, Smalberg JH, Spaander MC, Leebeek FW, Janssen HL. Long-term follow-up of patients with portal vein thrombosis and myeloproliferative neoplasms. *J Thromb Haemost* 2011;9:2208–2214.
- [47] Marchioli R, Finazzi G, Specchia G, Cacciola R, Cavazzina R, Cillonì D, et al. Cardiovascular events and intensity of treatment in polycythemia vera. *N Engl J Med* 2013;368:22–33.
- [48] Plessier A, Valla DC. Budd-Chiari syndrome. *Semin Liver Dis* 2008;28:259–269.
- [49] Hernandez-Guerra M, Turnes J, Rubinstein P, Olliff S, Elias E, Bosch J, et al. PTFE-covered stents improve TIPS patency in Budd-Chiari syndrome. *Hepatology* 2004;40:1197–1202.

- [50] Darwish MS, Valla DC, de Groen PC, Zeitoun G, Haagsma EB, Kuipers EJ, et al. Pathogenesis and treatment of Budd-Chiari syndrome combined with portal vein thrombosis. *Am J Gastroenterol* 2006;101:83–90.
- [51] Moucari R, Rautou PE, Cazals-Hatem D, Geara A, Bureau C, Consigny Y, et al. Hepatocellular carcinoma in Budd-Chiari syndrome: characteristics and risk factors. *Gut* 2008;57:828–835.
- [52] Plessier A, Sibert A, Consigny Y, Hakime A, Zappa M, Denninger MH, et al. Aiming at minimal invasiveness as a therapeutic strategy for Budd-Chiari syndrome. *Hepatology* 2006;44:1308–1316.
- [53] Seijo S, Plessier A, Hoekstra J, Dell'Era A, Mandair D, Rifai K, et al. Good long-term outcome of Budd-Chiari syndrome with a step-wise management. *Hepatology* 2013;57:1962–1968.
- [54] DeLeve LD, Valla DC, Garcia-Tsao G. Vascular disorders of the liver. *Hepatology* 2009;49:1729–1764.
- [55] Rautou PE, Douarin L, Denninger MH, Escolano S, Lebre C, Moreau R, et al. Bleeding in patients with Budd-Chiari syndrome. *J Hepatol* 2011;54:56–63.
- [56] Chagneau-Derode C, Roy L, guillot J, gloria O, Ollivier-Hourmand I, Bureau C, et al. Impact of cytoreductive therapy on the outcome of patients with myeloproliferative neoplasms and hepatosplanchnic vein thrombosis. *58 ed* 2013. p. 857A.
- [57] Sharma S, Texeira A, Texeira P, Elias E, Wilde J, Olliff SP. Pharmacological thrombolysis in Budd Chiari syndrome: a single centre experience and review of the literature. *J Hepatol* 2004;40:172–180.
- [58] Smalberg JH, Spaander MV, Jie KS, Pattynama PM, van Buuren HR, van den BB, et al. Risks and benefits of transcatheter thrombolytic therapy in patients with splanchnic venous thrombosis. *Thromb Haemost* 2008;100:1084–1088.
- [59] Valla D, Hadengue A, El Younsi M, Azar N, Zeitoun G, Boudet MJ, et al. Hepatic venous outflow block caused by short-length hepatic vein stenoses. *Hepatology* 1997;25:814–819.
- [60] Han G, Qi X, Zhang W, He C, Yin Z, Wang J, et al. Percutaneous recanalization for Budd-Chiari syndrome: an 11-year retrospective study on patency and survival in 177 Chinese patients from a single center. *Radiology* 2013;266:657–667.
- [61] Tilanus HW. Budd-Chiari syndrome. *Br J Surg* 1995;82:1023–1030.
- [62] Zeitoun G, Escolano S, Hadengue A, Azar N, El Younsi M, Mallet A, et al. Outcome of Budd-Chiari syndrome: a multivariate analysis of factors related to survival including surgical portosystemic shunting. *Hepatology* 1999;30:84–89.
- [63] Langlet P, Valla D. Is surgical portosystemic shunt the treatment of choice in Budd-Chiari syndrome? *Acta Gastroenterol Belg* 2002;65:155–160.
- [64] Panis Y, Belghiti J, Valla D, Benhamou JP, Fekete F. Portosystemic shunt in Budd-Chiari syndrome: long-term survival and factors affecting shunt patency in 25 patients in Western countries. *Surgery* 1994;115:276–281.
- [65] Bachet JB, Condat B, Hagege H, Plessier A, Consigny Y, Belghiti J, et al. Long-term portosystemic shunt patency as a determinant of outcome in Budd-Chiari syndrome. *J Hepatol* 2007;46:60–68.
- [66] Hemming AW, Langer B, Greig P, Taylor BR, Adams R, Heathcote EJ. Treatment of Budd-Chiari syndrome with portosystemic shunt or liver transplantation. *Am J Surg* 1996;171:176–180.
- [67] Garcia-Pagan JC, Heydtmann M, Raffa S, Plessier A, Murad S, Fabris F, et al. TIPS for Budd-Chiari syndrome: long-term results and prognostic factors in 124 patients. *Gastroenterology* 2008;135:808–815.
- [68] Mentha G, Giostra E, Majno PE, Bechstein WO, Neuhaus P, O'Grady J, et al. Liver transplantation for Budd-Chiari syndrome: a European study on 248 patients from 51 centres. *J Hepatol* 2006;44:520–528.
- [69] Segev DL, Nguyen GC, Locke JE, Simpkins CE, Montgomery RA, Maley WR, et al. Twenty years of liver transplantation for Budd-Chiari syndrome: a national registry analysis. *Liver Transpl* 2007;13:1285–1294.
- [70] Rautou PE, Angermayr B, Garcia-Pagan JC, Moucari R, Peck-Radosavljevic M, Raffa S, et al. Pregnancy in women with known and treated Budd-Chiari syndrome: maternal and fetal outcomes. *J Hepatol* 2009;51:47–54.
- [71] Perarnau JM, Bacq Y. Hepatic vascular involvement related to pregnancy, oral contraceptives, and estrogen replacement therapy. *Semin Liver Dis* 2008;28:315–327.
- [72] Bates SM, Greer IA, Pabinger I, Sofaer S, Hirsh J. Venous thromboembolism, thrombophilia, antithrombotic therapy, and pregnancy: American College of Chest Physicians Evidence-Based Clinical Practice Guidelines (8th Edition). *Chest* 2008;133:844S–886S.
- [73] Murad SD, Valla DC, de Groen PC, Zeitoun G, Hopmans JA, Haagsma EB, et al. Determinants of survival and the effect of portosystemic shunting in patients with Budd-Chiari syndrome. *Hepatology* 2004;39:500–508.
- [74] Rautou PE, Moucari R, Escolano S, Cazals-Hatem D, Denie C, Chagneau-Derode C, et al. Prognostic indices for Budd-Chiari syndrome: valid for clinical studies but insufficient for individual management. *Am J Gastroenterol* 2009;104:1140–1146.
- [75] de Franchis R. Revising consensus in portal hypertension: report of the Baveno V consensus workshop on methodology of diagnosis and therapy in portal hypertension. *J Hepatol* 2010;53:762–768.
- [76] Rajani R, Bjornsson E, Bergquist A, Danielsson A, Gustavsson A, Grip O, et al. The epidemiology and clinical features of portal vein thrombosis: a multicentre study. *Aliment Pharmacol Ther* 2010;32:1154–1162.
- [77] Turnes J, Garcia-Pagan JC, Gonzalez M, Aracil C, Calleja JL, Ripoll C, et al. Portal hypertension-related complications after acute portal vein thrombosis: impact of early anticoagulation. *Clin Gastroenterol Hepatol* 2008;6:1412–1417.
- [78] Condat B, Pessione F, Helene DM, Hillaire S, Valla D. Recent portal or mesenteric venous thrombosis: increased recognition and frequent recanalization on anticoagulant therapy. *Hepatology* 2000;32:466–470.
- [79] Acosta S, Alhadad A, Svensson P, Ekberg O. Epidemiology, risk and prognostic factors in mesenteric venous thrombosis. *Br J Surg* 2008;95:1245–1251.
- [80] Clavien PA, Durig M, Harder F. Venous mesenteric infarction: a particular entity. *Br J Surg* 1988;75:252–255.
- [81] Clavien PA, Harder F. Mesenteric venous thrombosis. An 18-year retrospective study. *Helv Chir Acta* 1988;55:29–34.
- [82] Kumar S, Sarr MG, Kamath PS. Mesenteric venous thrombosis. *N Engl J Med* 2001;345:1683–1688.
- [83] Hall TC, Garcea G, Metcalfe M, Bilku D, Dennison AR. Management of acute non-cirrhotic and non-malignant portal vein thrombosis: a systematic review. *World J Surg* 2011;35:2510–2520.
- [84] Elkrif L, Corcos O, Bruno O, Larroque B, Rautou PE, Zekrini K, et al. Type 2 diabetes mellitus as a risk factor for intestinal resection in patients with superior mesenteric vein thrombosis. *Liver Int* 2014;34(9):1314–1321.
- [85] Senzolo M, Riggio O, Primignani M. Vascular disorders of the liver: recommendations from the Italian Association for the Study of the Liver (AISF) ad hoc committee. *Dig Liver Dis* 2011;43:503–514.
- [86] Berzigotti A, Garcia-Criado A, Darnell A, Garcia-Pagan JC. Imaging in clinical decision-making for portal vein thrombosis. *Nat Rev Gastroenterol Hepatol* 2014;11(5):308–316.
- [87] Ferri PM, Rodrigues FA, Fagundes ED, Xavier SG, Dias RD, Fernandes AP, et al. Evaluation of the presence of hereditary and acquired thrombophilias in Brazilian children and adolescents with diagnoses of portal vein thrombosis. *J Pediatr Gastroenterol Nutr* 2012;55:599–604.
- [88] Randi ML, Tezza F, Scapin M, Duner E, Scarparo P, Scandellari R, et al. Heparin-induced thrombocytopenia in patients with Philadelphia-negative myeloproliferative disorders and unusual splanchnic or cerebral vein thrombosis. *Acta Haematol* 2010;123:140–145.
- [89] Ferro C, Rossi UG, Bovio G, Dahamane M, Centanaro M. Transjugular intrahepatic portosystemic shunt, mechanical aspiration thrombectomy, and direct thrombolysis in the treatment of acute portal and superior mesenteric vein thrombosis. *Cardiovasc Intervent Radiol* 2007;30:1070–1074.
- [90] Hollingshead M, Burke CT, Mauro MA, Weeks SM, Dixon RG, Jaques PF. Transcatheter thrombolytic therapy for acute mesenteric and portal vein thrombosis. *J Vasc Interv Radiol* 2005;16:651–661.
- [91] Liu FY, Wang MQ, Duan F, Wang ZJ, Song P. Interventional therapy for symptomatic-benign portal vein occlusion. *Hepatogastroenterology* 2010;57:1367–1374.
- [92] Wang MQ, Liu FY, Duan F, Wang ZJ, Song P, Fan QS. Acute symptomatic mesenteric venous thrombosis: treatment by catheter-directed thrombolysis with transjugular intrahepatic route. *Abdom Imaging* 2011;36:390–398.
- [93] Malkowski P, Pawlak J, Michalowicz B, Szczerban J, Wroblewski T, Leowska E, et al. Thrombolytic treatment of portal thrombosis. *Hepatogastroenterology* 2003;50:2098–2100.
- [94] Cao G, Ko GY, Sung KB, Yoon HK, Gwon D, Kim JH. Treatment of postoperative main portal vein and superior mesenteric vein thrombosis with balloon angioplasty and/or stent placement. *Acta Radiol* 2013;54(5):526–532.
- [95] Condat B, Valla D. Non malignant portal vein thrombosis. *Nat Clin Pract Gastroenterol Hepatol* 2006;3:505–515.
- [96] Chirinos JA, Garcia J, Alcaide ML, Toledo G, Baracco GJ, Lichtstein DM. Septic thrombophlebitis: diagnosis and management. *Am J Cardiovasc Drugs* 2006;6:9–14.
- [97] Llop E, de Juan C, Seijo S, Garcia-Criado A, Abalde JG, Bosch J, et al. Portal cholangiopathy: radiological classification and natural history. *Gut* 2011;60(6):853–860.
- [98] Abd El-Hamid N, Taylor RM, Marinello D, Mufti GJ, Patel R, Mieli-Vergani G, et al. Aetiology and management of extrahepatic portal vein obstruction in

# Clinical Practice Guidelines

children: King's College Hospital experience. *J Pediatr Gastroenterol Nutr* 2008;47:630–634.

- [99] Orr DW, Harrison PM, Devlin J, Karani JB, Kane PA, Heaton ND, et al. Chronic mesenteric venous thrombosis: evaluation and determinants of survival during long-term follow-up. *Clin Gastroenterol Hepatol* 2007;5:80–86.
- [100] Dhiman RK, Behera A, Chawla YK, Dilawari JB, Suri S. Portal hypertensive biliopathy. *Gut* 2007;56:1001–1008.
- [101] Rangari M, Gupta R, Jain M, Malhotra V, Sarin SK. Hepatic dysfunction in patients with extrahepatic portal venous obstruction. *Liver Int* 2003;23:434–439.
- [102] Minguez B, Garcia-Pagan JC, Bosch J, Turnes J, Alonso J, Rovira A, et al. Noncirrhotic portal vein thrombosis exhibits neuropsychological and MR changes consistent with minimal hepatic encephalopathy. *Hepatology* 2006;43:707–714.
- [103] Lautz TB, Sundaram SS, Whittington PF, Keys L, Superina RA. Growth impairment in children with extrahepatic portal vein obstruction is improved by mesenterico-left portal vein bypass. *J Pediatr Surg* 2009;44:2067–2070.
- [104] Marin D, Galluzzo A, Plessier A, Brancatelli G, Valla D, Vilgrain V. Focal nodular hyperplasia-like lesions in patients with cavernous transformation of the portal vein: prevalence, MR findings and natural history. *Eur Radiol* 2011;21:2074–2082.
- [105] Bradbury MS, Kavanagh PV, Chen MY, Weber TM, Bechtold RE. Noninvasive assessment of portomesenteric venous thrombosis: current concepts and imaging strategies. *J Comput Assist Tomogr* 2002;26:392–404.
- [106] Ueno N, Sasaki A, Tomiyama T, Tano S, Kimura K. Color Doppler ultrasonography in the diagnosis of cavernous transformation of the portal vein. *J Clin Ultrasound* 1997;25:227–233.
- [107] Vilgrain V, Condat B, Bureau C, Hakime A, Plessier A, Cazals-Hatem D, et al. Atrophy-hypertrophy complex in patients with cavernous transformation of the portal vein: CT evaluation. *Radiology* 2006;241:149–155.
- [108] Seijo S, Reverter E, Miquel R, Berzigotti A, Abraldes JG, Bosch J, et al. Role of hepatic vein catheterisation and transient elastography in the diagnosis of idiopathic portal hypertension. *Dig Liver Dis* 2012;44:855–860.
- [109] Koshy A, Girod C, Lee SS, Hadengue A, Cerini R, Lebre C. Discrepancy between portal pressure and systemic hemodynamic changes after incremental doses of propranolol in awake portal hypertensive rats. *Hepatology* 1989;9:269–273.
- [110] Braillon A, Moreau R, Hadengue A, Roulot D, Sayegh R, Lebre C. Hyperkinetic circulatory syndrome in patients with presinusoidal portal hypertension. Effect of propranolol. *J Hepatol* 1989;9:312–318.
- [111] Zargar SA, Javid G, Khan BA, Yattoo GN, Shah AH, Gulzar GM, et al. Endoscopic ligation compared with sclerotherapy for bleeding esophageal varices in children with extrahepatic portal venous obstruction. *Hepatology* 2002;36:666–672.
- [112] Sarin SK, Gupta N, Jha SK, Agrawal A, Mishra SR, Sharma BC, et al. Equal efficacy of endoscopic variceal ligation and propranolol in preventing variceal bleeding in patients with noncirrhotic portal hypertension. *Gastroenterology* 2010;139:1238–1245.
- [113] Orloff MJ, Orloff MS, Girard B, Orloff SL. Bleeding esophagogastric varices from extrahepatic portal hypertension: 40 years' experience with portal-systemic shunt. *J Am Coll Surg* 2002;194:717–728.
- [114] Fanelli F, Angeloni S, Salvatori FM, Marzano C, Boatta E, Merli M, et al. Transjugular intrahepatic portosystemic shunt with expanded-polytetrafluoroethylene-covered stents in non-cirrhotic patients with portal cavernoma. *Dig Liver Dis* 2011;43:78–84.
- [115] Mack CL, Zelko FA, Lokar J, Superina R, Alonso EM, Blei AT, et al. Surgically restoring portal blood flow to the liver in children with primary extrahepatic portal vein thrombosis improves fluid neurocognitive ability. *Pediatrics* 2006;117:e405–e412.
- [116] Superina RA, Alonso EM. Medical and surgical management of portal hypertension in children. *Curr Treat Options Gastroenterol* 2006;9:432–443.
- [117] Senzolo M, Tibbals J, Cholongitas E, Triantos CK, Burroughs AK, Patch D. Transjugular intrahepatic portosystemic shunt for portal vein thrombosis with and without cavernous transformation. *Aliment Pharmacol Ther* 2006;23:767–775.
- [118] Schouten JN, Garcia-Pagan JC, Valla DC, Janssen HL. Idiopathic noncirrhotic portal hypertension. *Hepatology* 2011;54:1071–1081.
- [119] Nakanuma Y, Hosono M, Sasaki M, Terada T, Katayanagi K, Nonomura A, et al. Histopathology of the liver in non-cirrhotic portal hypertension of unknown aetiology. *Histopathology* 1996;28:195–204.
- [120] Hillaire S, Bonte E, Denninger MH, Casadevall N, Cadranel JF, Lebre C, et al. Idiopathic non-cirrhotic intrahepatic portal hypertension in the West: a re-evaluation in 28 patients. *Gut* 2002;51:275–280.
- [121] Schouten JN, Nevens F, Hansen B, Laleman W, van den BM, Komuta M, et al. Idiopathic noncirrhotic portal hypertension is associated with poor survival: results of a long-term cohort study. *Aliment Pharmacol Ther* 2012;35:1424–1433.
- [122] Dhiman RK, Chawla Y, Vasishta RK, Kakkar N, Dilawari JB, Trehan MS, et al. Non-cirrhotic portal fibrosis (idiopathic portal hypertension): experience with 151 patients and a review of the literature. *J Gastroenterol Hepatol* 2002;17:6–16.
- [123] Krasinskas AM, Egtesad B, Kamath PS, Demetris AJ, Abraham SC. Liver transplantation for severe intrahepatic noncirrhotic portal hypertension. *Liver Transpl* 2005;11:627–634.
- [124] Chang PE, Miquel R, Blanco JL, Laguno M, Bruguera M, Abraldes JG, et al. Idiopathic portal hypertension in patients with HIV infection treated with highly active antiretroviral therapy. *Am J Gastroenterol* 2009;104:1707–1714.
- [125] Seijo S, Lozano JJ, Alonso C, Reverter E, Miquel R, Abraldes JG, et al. Metabolomics discloses potential biomarkers for the noninvasive diagnosis of idiopathic portal hypertension. *Am J Gastroenterol* 2013;108:926–932.
- [126] Ibarrola C, Colina F. Clinicopathological features of nine cases of non-cirrhotic portal hypertension: current definitions and criteria are inadequate. *Histopathology* 2003;42:251–264.
- [127] Verheij J, Schouten JN, Komuta M, Nevens F, Hansen BE, Janssen HL, et al. Histological features in western patients with idiopathic non-cirrhotic portal hypertension. *Histopathology* 2013;62:1083–1091.
- [128] Wanless IR. Micronodular transformation (nodular regenerative hyperplasia) of the liver: a report of 64 cases among 2,500 autopsies and a new classification of benign hepatocellular nodules. *Hepatology* 1990;11:787–797.
- [129] Siramolpiwat S, Seijo S, Miquel R, Berzigotti A, Garcia-Criado A, Darnell A, et al. Idiopathic portal hypertension: Natural history and long-term outcome. *Hepatology* 2014;59(6):2276–2285.
- [130] Chawla YK, Dilawari JB, Dhiman RK, Goenka MK, Bhasin DK, Kochhar R, et al. Sclerotherapy in noncirrhotic portal fibrosis. *Dig Dis Sci* 1997;42:1449–1453.
- [131] Bhargava DK, Dasarathy S, Sundaram KR, Ahuja RK. Efficacy of endoscopic sclerotherapy on long-term management of oesophageal varices: a comparative study of results in patients with cirrhosis of the liver, non-cirrhotic portal fibrosis (NCPF) and extrahepatic portal venous obstruction (EHO). *J Gastroenterol Hepatol* 1991;6:471–475.
- [132] Schiano TD, Kotler DP, Ferran E, Fiel MI. Hepatoportal sclerosis as a cause of noncirrhotic portal hypertension in patients with HIV. *Am J Gastroenterol* 2007;102:2536–2540.
- [133] Govani FS, Shovlin CL. Hereditary haemorrhagic telangiectasia: a clinical and scientific review. *Eur J Hum Genet* 2009;17:860–871.
- [134] Shovlin CL, Guttmacher AE, Buscarini E, Faughnan ME, Hyland RH, Westermann CJ, et al. Diagnostic criteria for hereditary hemorrhagic telangiectasia (Rendu-Osler-Weber syndrome). *Am J Med Genet* 2000;91:66–67.
- [135] Buscarini E, Leandro G, Conte D, Danesino C, Daina E, Manfredi G, et al. Natural history and outcome of hepatic vascular malformations in a large cohort of patients with hereditary hemorrhagic telangiectasia. *Dig Dis Sci* 2011;56:2166–2178.
- [136] Memeo M, Stabile Ianora AA, Scardapane A, Suppressa P, Cirulli A, Sabba C, et al. Hereditary haemorrhagic telangiectasia: study of hepatic vascular alterations with multi-detector row helical CT and reconstruction programs. *Radiol Med* 2005;109:125–138.
- [137] Lesca G, Olivieri C, Burnichon N, Pagella F, Carette MF, Gilbert-Dussardier B, et al. Genotype-phenotype correlations in hereditary hemorrhagic telangiectasia: data from the French-Italian HHT network. *Genet Med* 2007;9:14–22.
- [138] Letteboer TG, Mager HJ, Snijder RJ, Lindhout D, Ploos van Amstel HK, Zanen P, et al. Genotype-phenotype relationship for localization and age distribution of telangiectases in hereditary hemorrhagic telangiectasia. *Am J Med Genet A* 2008;146A:2733–2739.
- [139] Buscarini E, Danesino C, Olivieri C, Lupinacci G, De GF, Reduzzi L, et al. Doppler ultrasonographic grading of hepatic vascular malformations in hereditary hemorrhagic telangiectasia – results of extensive screening. *Ultraschall Med* 2004;25:348–355.
- [140] Garcia-Tsao G, Korzenik JR, Young L, Henderson KJ, Jain D, Byrd B, et al. Liver disease in patients with hereditary hemorrhagic telangiectasia. *N Engl J Med* 2000;343:931–936.
- [141] Buscarini E, Danesino C, Plauchu H, de Fazio C, Olivieri C, Brambilla G, et al. High prevalence of hepatic focal nodular hyperplasia in subjects with hereditary hemorrhagic telangiectasia. *Ultrasound Med Biol* 2004;30:1089–1097.

- [142] Buscarini E, Plauchu H, Garcia TG, White Jr RI, Sabba C, Miller F, et al. Liver involvement in hereditary hemorrhagic telangiectasia: consensus recommendations. *Liver Int* 2006;26:1040–1046.
- [143] Faughnan ME, Palda VA, Garcia-Tsao G, Geisthoff UW, McDonald J, Proctor DD, et al. International guidelines for the diagnosis and management of hereditary haemorrhagic telangiectasia. *J Med Genet* 2011;48:73–87.
- [144] Lerut J, Orlando G, Adam R, Sabba C, Pfizmann R, Klempnauer J, et al. Liver transplantation for hereditary hemorrhagic telangiectasia: report of the European liver transplant registry. *Ann Surg* 2006;244:854–862.
- [145] Dupuis-Girod S, Chesnais AL, Ginon I, Dumortier J, Saurin JC, Finet G, et al. Long-term outcome of patients with hereditary hemorrhagic telangiectasia and severe hepatic involvement after orthotopic liver transplantation: a single-center study. *Liver Transpl* 2010;16:340–347.
- [146] Buonamico P, Suppressa P, Lenato GM, Pasculli G, D'Ovidio F, Memeo M, et al. Liver involvement in a large cohort of patients with hereditary hemorrhagic telangiectasia: echo-color-Doppler vs. multislice computed tomography study. *J Hepatol* 2008;48:811–820.
- [147] Buscarini E, Gebel M, Ocran K, Manfredi G, Del Vecchio BG, Stefanov R, et al. Interobserver agreement in diagnosing liver involvement in hereditary hemorrhagic telangiectasia by Doppler ultrasound. *Ultrasound Med Biol* 2008;34:718–725.
- [148] Gincul R, Lesca G, Gelas-Dore B, Rollin N, Barthelet M, Dupuis-Girod S, et al. Evaluation of previously nonscreened hereditary hemorrhagic telangiectasia patients shows frequent liver involvement and early cardiac consequences. *Hepatology* 2008;48:1570–1576.
- [149] Chavan A, Luthe L, Gebel M, Barg-Hock H, Seifert H, Raab R, et al. Complications and clinical outcome of hepatic artery embolisation in patients with hereditary haemorrhagic telangiectasia. *Eur Radiol* 2013;23:951–957.
- [150] Dupuis-Girod S, Ginon I, Saurin JC, Marion D, Guillot E, Decullier E, et al. Bevacizumab in patients with hereditary hemorrhagic telangiectasia and severe hepatic vascular malformations and high cardiac output. *JAMA* 2012;307:948–955.
- [151] Rubbia-Brandt L. Sinusoidal obstruction syndrome. *Clin Liver Dis* 2010;14:651–668.
- [152] DeLeve LD, McCuskey RS, Wang X, Hu L, McCuskey MK, Epstein RB, et al. Characterization of a reproducible rat model of hepatic veno-occlusive disease. *Hepatology* 1999;29:1779–1791.
- [153] McDonald GB, Slattery JT, Bouvier ME, Ren S, Batchelder AL, Kalhorn TF, et al. Cyclophosphamide metabolism, liver toxicity, and mortality following hematopoietic stem cell transplantation. *Blood* 2003;101:2043–2048.
- [154] Coppell JA, Richardson PG, Soiffer R, Martin PL, Kernan NA, Chen A, et al. Hepatic veno-occlusive disease following stem cell transplantation: incidence, clinical course, and outcome. *Biol Blood Marrow Transplant* 2010;16:157–168.
- [155] Angliviel B, Benoist S, Penna C, El HM, Chagnon S, Julie C, et al. Impact of chemotherapy on the accuracy of computed tomography scan for the evaluation of colorectal liver metastases. *Ann Surg Oncol* 2009;16:1247–1253.
- [156] Aloia T, Sebah M, Plasse M, Karam V, Levi F, Giacchetti S, et al. Liver histology and surgical outcomes after preoperative chemotherapy with fluorouracil plus oxaliplatin in colorectal cancer liver metastases. *J Clin Oncol* 2006;24:4983–4990.
- [157] Nakano H, Oussoultzoglou E, Rosso E, Casnedi S, Chenard-Neu MP, Dufour P, et al. Sinusoidal injury increases morbidity after major hepatectomy in patients with colorectal liver metastases receiving preoperative chemotherapy. *Ann Surg* 2008;247:118–124.
- [158] Chun YS, Laurent A, Maru D, Vauthey JN. Management of chemotherapy-associated hepatotoxicity in colorectal liver metastases. *Lancet Oncol* 2009;10:278–286.
- [159] Mentha G, Majno P, Terraz S, Rubbia-Brandt L, Gervaz P, Andres A, et al. Treatment strategies for the management of advanced colorectal liver metastases detected synchronously with the primary tumour. *Eur J Surg Oncol* 2007;33:576–583.
- [160] Overman MJ, Maru DM, Charnsangavej C, Loyer EM, Wang H, Pathak P, et al. Oxaliplatin-mediated increase in spleen size as a biomarker for the development of hepatic sinusoidal injury. *J Clin Oncol* 2010;28:2549–2555.
- [161] Soubrane O, Brouquet A, Zalinski S, Terris B, Brezault C, Mallet V, et al. Predicting high grade lesions of sinusoidal obstruction syndrome related to oxaliplatin-based chemotherapy for colorectal liver metastases: correlation with post-hepatectomy outcome. *Ann Surg* 2010;251:454–460.
- [162] Slade JH, Alattar ML, Fogelman DR, Overman MJ, Agarwal A, Maru DM, et al. Portal hypertension associated with oxaliplatin administration: clinical manifestations of hepatic sinusoidal injury. *Clin Colorectal Cancer* 2009;8:225–230.
- [163] Miura K, Nakano H, Sakurai J, Kobayashi S, Koizumi S, Arai T, et al. Splenomegaly in FOLFOX-naive stage IV or recurrent colorectal cancer patients due to chemotherapy-associated hepatotoxicity can be predicted by the aspartate aminotransferase to platelet ratio before chemotherapy. *Int J Clin Oncol* 2011;16:257–263.
- [164] Angitapalli R, Litwin AM, Kumar PR, Nasser E, Lombardo J, Mashtare T, et al. Adjuvant FOLFOX chemotherapy and splenomegaly in patients with stages II–III colorectal cancer. *Oncology* 2009;76:363–368.
- [165] Mahgerefteh SY, Sosna J, Bogot N, Shapira MY, Pappo O, Bloom AI. Radiologic imaging and intervention for gastrointestinal and hepatic complications of hematopoietic stem cell transplantation. *Radiology* 2011;258:660–671.
- [166] Ward J, Guthrie JA, Sheridan MB, Boyes S, Smith JT, Wilson D, et al. Sinusoidal obstructive syndrome diagnosed with superparamagnetic iron oxide-enhanced magnetic resonance imaging in patients with chemotherapy-treated colorectal liver metastases. *J Clin Oncol* 2008;26:4304–4310.
- [167] O'Rourke TR, Welsh FK, Tekkis PP, Lyle N, Mustajab A, John TG, et al. Accuracy of liver-specific magnetic resonance imaging as a predictor of chemotherapy-associated hepatic cellular injury prior to liver resection. *Eur J Surg Oncol* 2009;35:1085–1091.
- [168] Shin NY, Kim MJ, Lim JS, Park MS, Chung YE, Choi JY, et al. Accuracy of gadoxetic acid-enhanced magnetic resonance imaging for the diagnosis of sinusoidal obstruction syndrome in patients with chemotherapy-treated colorectal liver metastases. *Eur Radiol* 2012;22:864–871.
- [169] Shulman HM, Fisher LB, Schoch HG, Henne KW, McDonald GB. Veno-occlusive disease of the liver after marrow transplantation: histological correlates of clinical signs and symptoms. *Hepatology* 1994;19:1171–1181.
- [170] Carreras E, Granena A, Navasa M, Bruguera M, Marco V, Sierra J, et al. On the reliability of clinical criteria for the diagnosis of hepatic veno-occlusive disease. *Ann Hematol* 1993;66:77–80.
- [171] Rubbia-Brandt L, Audard V, Sartoretti P, Roth AD, Brezault C, Le CM, et al. Severe hepatic sinusoidal obstruction associated with oxaliplatin-based chemotherapy in patients with metastatic colorectal cancer. *Ann Oncol* 2004;15:460–466.
- [172] Rubbia-Brandt L, Lauwers GY, Wang H, Majno PE, Tanabe K, Zhu AX, et al. Sinusoidal obstruction syndrome and nodular regenerative hyperplasia are frequent oxaliplatin-associated liver lesions and partially prevented by bevacizumab in patients with hepatic colorectal metastasis. *Histopathology* 2010;56:430–439.
- [173] Shulman HM, Gooley T, Dudley MD, Kofler T, Feldman R, Dwyer D, et al. Utility of transvenous liver biopsies and wedged hepatic venous pressure measurements in sixty marrow transplant recipients. *Transplantation* 1995;59:1015–1022.
- [174] Esposito AA, Nicolini A, Meregaglia D, Sangiovanni A, Biondetti P. Role of transjugular liver biopsy in the diagnostic and therapeutic management of patients with severe liver disease. *Radiol Med* 2008;113:1008–1017.
- [175] Brouquet A, Benoist S, Julie C, Beauchet A, Rougier P, et al. Risk factors for chemotherapy-associated liver injuries: A multivariate analysis of a group of 146 patients with colorectal metastases. *Surgery* 2009;145:362–371.
- [176] Goekkur E, Stoehlmacher J, Stueber C, Wolschke C, Eiermann T, Iacobelli S, et al. Pharmacogenetic analysis of liver toxicity after busulfan/cyclophosphamide-based allogeneic hematopoietic stem cell transplantation. *Anticancer Res* 2007;27:4377–4380.
- [177] Corbacioglu S, Cesaro S, Faraci M, Valteau-Couanet D, Gruhn B, Rovelli A, et al. Defibrotide for prophylaxis of hepatic veno-occlusive disease in paediatric haemopoietic stem-cell transplantation: an open-label, phase 3, randomised controlled trial. *Lancet* 2012;379:1301–1309.
- [178] Imran H, Tleyjeh IM, Zirakzadeh A, Rodriguez V, Khan SP. Use of prophylactic anticoagulation and the risk of hepatic veno-occlusive disease in patients undergoing hematopoietic stem cell transplantation: a systematic review and meta-analysis. *Bone Marrow Transplant* 2006;37:677–686.
- [179] Richardson PG, Soiffer RJ, Antin JH, Uno H, Jin Z, Kurtzberg J, et al. Defibrotide for the treatment of severe hepatic veno-occlusive disease and multiorgan failure after stem cell transplantation: a multicenter, randomized, dose-finding trial. *Biol Blood Marrow Transplant* 2010;16:1005–1017.
- [180] Northrup PG, McMahon MM, Ruhl AP, Altschuler SE, Volk-Bednarz A, Caldwell SH, et al. Coagulopathy does not fully protect hospitalized cirrhotic patients from peripheral venous thromboembolism. *Am J Gastroenterol* 2006;101:1524–1528.
- [181] Sogaard KK, Horvath-Puho E, Gronbaek H, Jepsen P, Vilstrup H, Sorensen HT. Risk of venous thromboembolism in patients with liver disease: a

# Clinical Practice Guidelines

- nationwide population-based case-control study. *Am J Gastroenterol* 2009;104:96–101.
- [182] Tripodi A, Mannucci PM. The coagulopathy of chronic liver disease. *N Engl J Med* 2011;365:147–156.
- [183] Rodriguez-Castro KI, Porte RJ, Nadal E, Germani G, Burra P, Senzolo M. Management of nonneoplastic portal vein thrombosis in the setting of liver transplantation: a systematic review. *Transplantation* 2012;94:1145–1153.
- [184] Francoz C, Belghiti J, Vilgrain V, Sommacale D, Paradis V, Condat B, et al. Splanchnic vein thrombosis in candidates for liver transplantation: usefulness of screening and anticoagulation. *Gut* 2005;54:691–697.
- [185] Zocco MA, Di SE, De CR, Novi M, Ainora ME, Ponziani F, et al. Thrombotic risk factors in patients with liver cirrhosis: correlation with MELD scoring system and portal vein thrombosis development. *J Hepatol* 2009;51:682–689.
- [186] Ogren M, Bergqvist D, Bjorck M, Acosta S, Eriksson H, Sternby NH. Portal vein thrombosis: prevalence, patient characteristics and lifetime risk: a population study based on 23,796 consecutive autopsies. *World J Gastroenterol* 2006;12:2115–2119.
- [187] Amitrano L, Guardascione MA, Scaglione M, Menchise A, Martino R, Manguso F, et al. Splanchnic vein thrombosis and variceal rebleeding in patients with cirrhosis. *Eur J Gastroenterol Hepatol* 2012;24:1381–1385.
- [188] Augustin S, Altamirano J, Gonzalez A, Dot J, Abu-Suboh M, Armengol JR, et al. Effectiveness of combined pharmacologic and ligation therapy in high-risk patients with acute esophageal variceal bleeding. *Am J Gastroenterol* 2011;106:1787–1795.
- [189] D'Amico G, de Franchis R. Upper digestive bleeding in cirrhosis. Post-therapeutic outcome and prognostic indicators. *Hepatology* 2003;38:599–612.
- [190] Amitrano L, Guardascione MA, Brancaccio V, Margaglione M, Manguso F, Iannaccone L, et al. Risk factors and clinical presentation of portal vein thrombosis in patients with liver cirrhosis. *J Hepatol* 2004;40:736–741.
- [191] Englesbe MJ, Kubus J, Muhammad W, Sonnenday CJ, Welling T, Punch JD, et al. Portal vein thrombosis and survival in patients with cirrhosis. *Liver Transpl* 2010;16:83–90.
- [192] Amitrano L, Brancaccio V, Guardascione MA, Margaglione M, Sacco M, Martino R, et al. Portal vein thrombosis after variceal endoscopic sclerotherapy in cirrhotic patients: role of genetic thrombophilia. *Endoscopy* 2002;34:535–538.
- [193] Erkan O, Bozdayi AM, Disibeyaz S, Oguz D, Ozcan M, Bahar K, et al. Thrombophilic gene mutations in cirrhotic patients with portal vein thrombosis. *Eur J Gastroenterol Hepatol* 2005;17:339–343.
- [194] Tublin ME, Dodd III GD, Baron RL. Benign and malignant portal vein thrombosis: differentiation by CT characteristics. *AJR Am J Roentgenol* 1997;168:719–723.
- [195] Rossi S, Rosa L, Ravetta V, Cascina A, Quaretti P, Azzaretti A, et al. Contrast-enhanced versus conventional and color Doppler sonography for the detection of thrombosis of the portal and hepatic venous systems. *AJR Am J Roentgenol* 2006;186:763–773.
- [196] Villa E, Camma C, Marietta M, Luongo M, Critelli R, Colopi S, et al. Enoxaparin prevents portal vein thrombosis and liver decompensation in patients with advanced cirrhosis. *Gastroenterology* 2012;143:1253–1260.
- [197] Luca A, Caruso S, Milazzo M, Marrone G, Mamone G, Crino F, et al. Natural course of extrahepatic nonmalignant partial portal vein thrombosis in patients with cirrhosis. *Radiology* 2012;265:124–132.
- [198] Nery F, Chevret S, Condat B, De RE, Boudaoud L, Rautou PE, et al. Causes and consequences of portal vein thrombosis in 1,243 patients with cirrhosis: results of a longitudinal study. *Hepatology* 2015;61:660–667.
- [199] Senzolo M, Sartori M, Rossetto V, Burra P, Cillo U, Boccagni P, et al. Prospective evaluation of anticoagulation and transjugular intrahepatic portosystemic shunt for the management of portal vein thrombosis in cirrhosis. *Liver Int* 2012;32:919–927.
- [200] Amitrano L, Guardascione MA, Menchise A, Martino R, Scaglione M, Giovine S, et al. Safety and efficacy of anticoagulation therapy with low molecular weight heparin for portal vein thrombosis in patients with liver cirrhosis. *J Clin Gastroenterol* 2010;44:448–451.
- [201] Delgado MG, Seijo S, Yepes I, Achecar L, Catalina MV, Garcia-Criado A, et al. Efficacy and Safety of Anticoagulation on Patients With Cirrhosis and Portal Vein Thrombosis. *Clin Gastroenterol Hepatol* 2012;10:776–783.
- [202] Werner KT, Sando S, Carey EJ, Vargas HE, Byrne TJ, Douglas DD, et al. Portal vein thrombosis in patients with end stage liver disease awaiting liver transplantation: outcome of anticoagulation. *Dig Dis Sci* 2013;58(6):1776–1780.
- [203] Luca A, Miraglia R, Caruso S, Milazzo M, Sapere C, Maruzzelli L, et al. Short- and long-term effects of the transjugular intrahepatic portosystemic shunt on portal vein thrombosis in patients with cirrhosis. *Gut* 2011;60(6):846–852.
- [204] Perarnau JM, Baju A, d'Alteroche L, Viguier J, Ayoub J. Feasibility and long-term evolution of TIPS in cirrhotic patients with portal thrombosis. *Eur J Gastroenterol Hepatol* 2010;22:1093–1098.
- [205] Han G, Qi X, He C, Yin Z, Wang J, Xia J, et al. Transjugular intrahepatic portosystemic shunt for portal vein thrombosis with symptomatic portal hypertension in liver cirrhosis. *J Hepatol* 2011;54:78–88.
- [206] Senzolo M, Patch D, Burra P, Burroughs AK. Tips for portal vein thrombosis (PVT) in cirrhosis: not only unblocking a pipe. *J Hepatol* 2011;55(4):945–946.
- [207] Kearon C, Akl EA, Comerota AJ, Prandoni P, Bounameaux H, Goldhaber SZ, et al. Antithrombotic therapy for VTE disease: Antithrombotic Therapy and Prevention of Thrombosis, 9th ed.: American College of Chest Physicians Evidence-Based Clinical Practice Guidelines. *Chest* 2012;141:e419S–e494S.
- [208] Garcia DA, Baglin TP, Weitz JI, Samama MM. Parenteral anticoagulants: Antithrombotic Therapy and Prevention of Thrombosis, 9th ed.: American College of Chest Physicians Evidence-Based Clinical Practice Guidelines. *Chest* 2012;141:e245S–e435S.
- [209] Rodriguez-Castro KI, Simioni P, Burra P, Senzolo M. Anticoagulation for the treatment of thrombotic complications in patients with cirrhosis. *Liver Int* 2012;32:1465–1476.
- [210] Bechmann LP, Wichert M, Kroger K, Hilgard P. Dosing and monitoring of low-molecular-weight heparin in cirrhotic patients. *Liver Int* 2011;31:1064.
- [211] Lisman T, Porte RJ. Towards a rational use of low-molecular-weight heparin in patients with cirrhosis. *Liver Int* 2011;31:1063.
- [212] Senzolo M, Rodriguez-Castro KI, Rossetto V, Radu C, Gavasso S, Carraro P, et al. Increased anticoagulant response to low-molecular-weight heparin in plasma from patients with advanced cirrhosis. *J Thromb Haemost* 2012;10:1823–1829.
- [213] Ageno W, Gallus AS, Wittkowsky A, Crowther M, Hylek EM, Palareti G. Oral anticoagulant therapy: Antithrombotic Therapy and Prevention of Thrombosis, 9th ed.: American College of Chest Physicians Evidence-Based Clinical Practice Guidelines. *Chest* 2012;141:e445S–e885S.
- [214] van den Besselaar AM, Barrowcliffe TW, Houbouyan-Reveillard LL, Jespersen J, Johnston M, Poller L, et al. Guidelines on preparation, certification, and use of certified plasmas for ISI calibration and INR determination. *J Thromb Haemost* 2004;2:1946–1953.
- [215] Tripodi A, Chantarangkul V, Mannucci PM. The international normalized ratio to prioritize patients for liver transplantation: problems and possible solutions. *J Thromb Haemost* 2008;6:243–248.
- [216] Tripodi A, Palareti G. New anticoagulant drugs for treatment of venous thromboembolism and stroke prevention in atrial fibrillation. *J Intern Med* 2012;271:554–565.
- [217] Liakoni E, Ratz Bravo AE, Terracciano L, Heim M, Krahenbuhl S. Symptomatic hepatocellular liver injury with hyperbilirubinemia in two patients treated with rivaroxaban. *JAMA Intern Med* 2014;174:1683–1686.